


Volume 38 • Number 6
November/December 2014



JOURNAL OF COMPUTER ASSISTED TOMOGRAPHY

Full Text
OVID

www.jcat.org



J
C
A
T

Allen D. Elster
Editor-in-Chief

**WEB-BASED MANUSCRIPT
SUBMISSION NOW AVAILABLE!**
See journal Web site for details.



Wolters Kluwer
Health

Lippincott
Williams & Wilkins

MR Cholangiopancreatography Before and After Oral Blueberry Juice Administration

Papanikolaou, Nikolaos; Karantanas, Apostolos; Maris, Thomas; Gourtsoyiannis, Nickolas

Journal of Computer Assisted Tomography . 24(2):229-234, March/April 2000.

Author Information

From MR Clinical Science, Philips Medical Systems (N. Papanikolaou), Department of CT-MRI, Larissa General Hospital, Larissa (A. Karantanas), and Department of Radiology, University of Crete-Heraklion, Crete (T. Maris and N. Gourtsoyiannis), Greece. This article was given as an oral presentation at RSNA '98. Address correspondence and reprint requests to Dr. A. Karantanas at Department of CT-MRI, Larissa General Hospital, 1 Tsakalof St., Larissa 412 21, Greece. E-mail: apolsen@yahoo.com

Abstract

Abstract: Blueberry juice was used in 37 patients who underwent MR cholangiopancreatography (MRCP) examination. Quantitative and qualitative comparison between pre- and post-blueberry juice oral administration was made. Common bile duct and main pancreatic duct depiction improved statistically significantly ($p < 0.05$) after blueberry juice administration. Blueberry juice may be used routinely in MRCP studies as a natural, safe, and inexpensive negative contrast agent with high efficacy.

Recently, several investigators have discussed the diagnostic performance of MR cholangiopancreatography (MRCP) as a noninvasive method applied with 2D and 3D turbo spin echo (2D and 3D TSE) and with single shot TSE and half-Fourier TSE (SSTSE and HASTE) sequences (1-7). Respiratory artifacts were minimized by using respiratory triggering technique (RT) with 3D TSE or breath-hold (BH) technique with SSTSE and HASTE (8,9). However, overlap between the pancreatobiliary tree and high intensity structures like the stomach, duodenum, and proximal intestine (10) is a recognized limitation, especially in projectional techniques like SSTSE. This drawback could be overcome either by using multiple acquisitions of the same sequence planned in different angulations or by using negative contrast agents for the gastrointestinal tract to reduce high signal intensities arising from adjacent tissues (5). Various oral negative contrast agents for T2-weighted imaging in abdominal applications have been proposed (11-16). Hiraishi et al. (17) first used blueberry juice as an oral negative contrast agent in gastrointestinal MRI. They concluded that blueberry juice at appropriate concentrations could be an effective positive oral contrast agent on T1-weighted images and negative contrast agent on T2-weighted images. Experimental use of blueberry juice was also reported by Hirohashi et al. (10) to suppress high signal intensities in heavily T2-weighted images on phantoms.

The purpose of our study was to evaluate the use of blueberry juice as a negative oral contrast agent for the gastrointestinal tract in MRCP studies.

[Back to Top](#)

MATERIALS AND METHODS

Blueberry Juice Phantom Measurements

The contents of iron (Fe^{3+}) and manganese (Mn^{2+}) ions were determined in tinned myrtilles in syrup. The contents of three cans were processed according to the method reported by Challa et al. (18). The results given are the means of the contents of the three cans. Iron was determined photometrically with the reagents of a kit by Elitech Diagnostics. Manganese was measured by atomic absorption on a spectrophotometer (Perkin-Elmer model 560).

[Back to Top](#)

Subjects

Thirty-seven patients with clinically suspected obstructive jaundice underwent 3D TSE RT and 2D SSTSE BH. The patient population consisted of 18 men and 19 women. The average age was 64.4 years (range 31–87 years). All patients were informed about the nature and the purpose of the procedure, and informed consent was obtained from all subjects prior to examination. All subjects were studied before and after 430 ml of blueberry juice was administered orally. The juice was given as follows: 150 ml 30 min before scanning, 150 ml 15 min before scanning, and 130 ml just before scanning. Patients were asked to fast for >6 h before undergoing the MRCP examination.

[Back to Top](#)

MRI

All MR examinations were performed on a Gyroscan NT T10 superconductive MR system (Philips Medical Systems, Best, The Netherlands) using commercial available software (Rel 4.5) and maximum gradient strength of 15 mT/m (Figs. 1–3). The quadrature body coil was used as a transmitter in all cases and receiver in 28 of 37 cases. In nine cases of thin patients, a circular surface coil (17 cm diameter) was used on the anterior abdominal wall at the level of the biliary tree. A 3D multislab heavily T2-weighted TSE sequence with spectral fat suppression prepulse (SPIR) was utilized. Eight overlapping slabs were used. Each slab was 17.62 mm thick with 41% overlap between adjacent slabs. Each slab was divided into 10 partitions with 2.5 mm thickness and 50% overlap between adjacent partitions. The total volume size was 10 cm, and the orientation of the slices in the coronal plane. Two-dimensional SSTSE was applied in the coronal plane, and the thickness of the projectional slice was 70–100 mm. The phase-encoding direction for both sequences was left to right. The rest of the sequence parameters are shown in [Table 1](#).

Sequence	3D TSE RT	SSTSE
TR (ms)	1,800–2,500	4,000
TE (ms)	1,000	1,300
Echo train length	128	274 ^a
Echo spacing (ms)	15.5	10.6
Matrix size	160 × 256	205 × 256
Field of view	320 × 400 mm ² body coil, 210 × 300 mm ² surface coil	320 × 400 mm ² body coil, 216 × 270 mm ² surface coil
Scan time	12–14 min	8 s

3D TSE RT, 3D turbo spin echo with respiratory triggering technique; SSTSE, single shot turbo spin echo.

^aIn this sequence, the first 18 echoes (dummy echoes) were excited but not measured to eliminate artifacts arising from tissues with short T2.

TABLE 1. Pulse sequence parameters 3D TSE RT, 3D turbo spin echo with respiratory triggering technique; SSTSE, single shot turbo spin echo. In this sequence, the first 18 echoes (dummy echoes) were excited but not measured to eliminate artifacts arising from tissues with short T2.

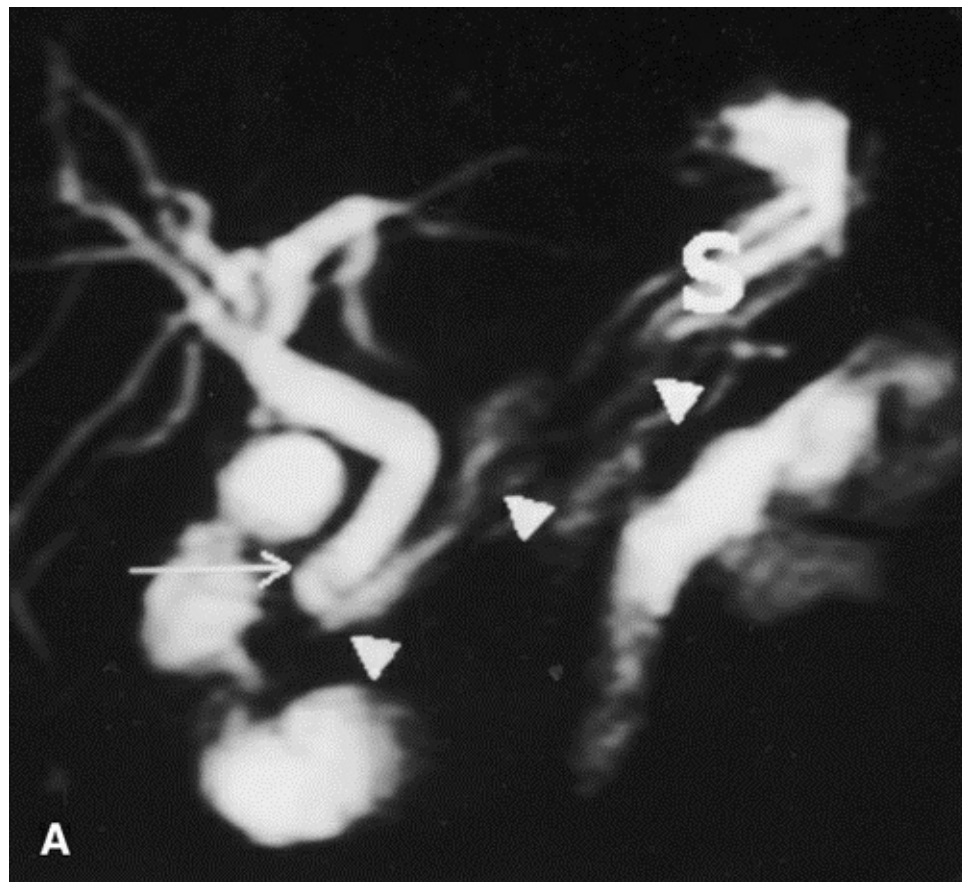


FIG. 1. Patient with choledocholithiasis. A: Single shot turbo spin echo sequence before blueberry juice administration demonstrated the presence of a stone in the distal common bile duct (arrow). B: In the same sequence after blueberry juice administration, stone visualization was improved (arrow). Note the improvement for depiction of the main pancreatic duct (arrowheads) and especially at the junction area of the main pancreatic duct and the distal common bile duct after blueberry juice administration. High signal intensities of stomach [S] were eliminated, improving the distal and proximal delineation of the main pancreatic duct.

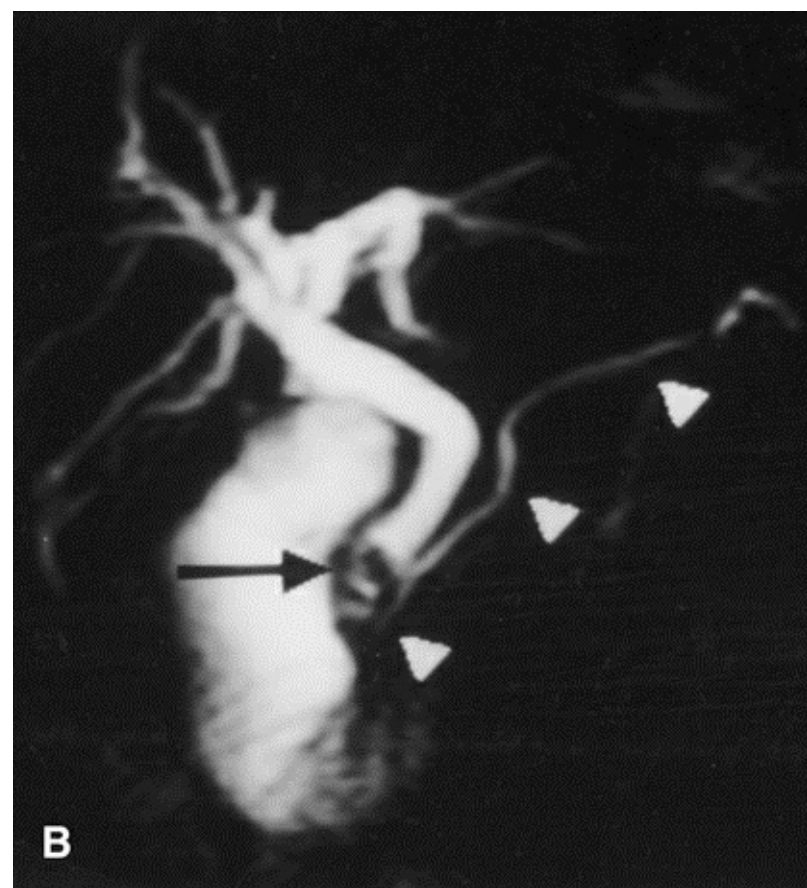


Figure 1. Continued

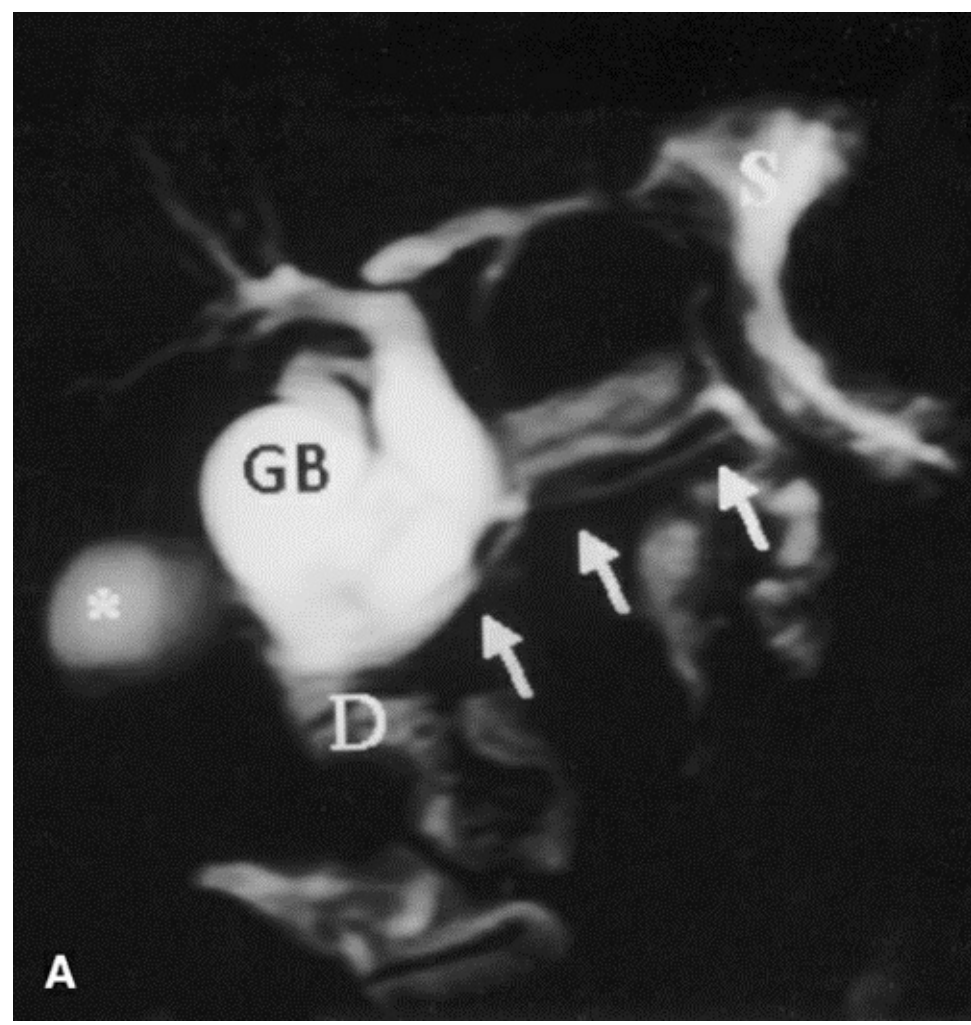


FIG. 2. Patient with double pancreatic duct. Shown are single shot turbo spin echo (SSTSE) images before (A) and after (B) blueberry juice administration and 3D turbo spin echo maximum intensity projection (3D TSE MIP) images before (C) and after (D) blueberry juice administration. Signals from stomach [S] and duodenum [D] were suppressed, improving the depiction of pancreatic duct (arrows) in SSTSE (A and B) and both pancreatic duct (arrowheads) and the junction of the common bile duct and the main pancreatic duct (arrow) in 3D TSE MIP (C and D). *, renal cyst; GB, gallbladder.

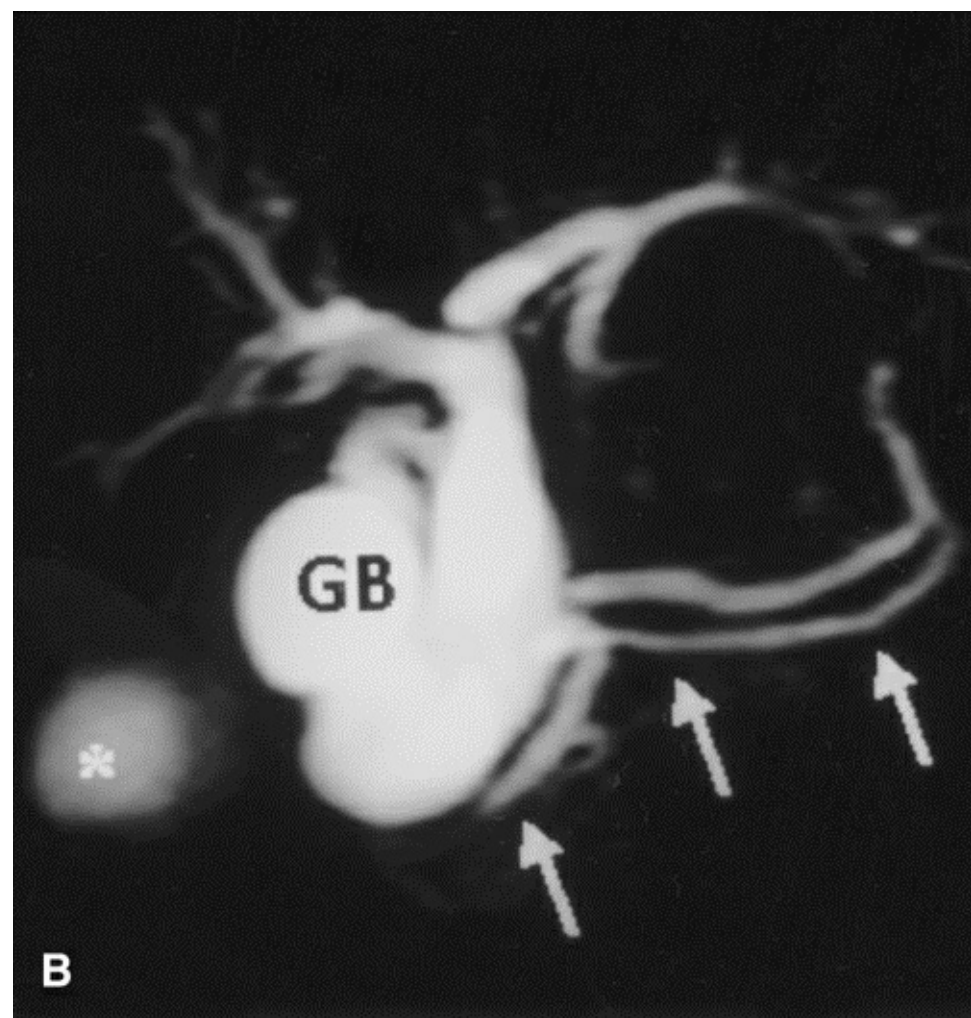


Figure 2. Continued

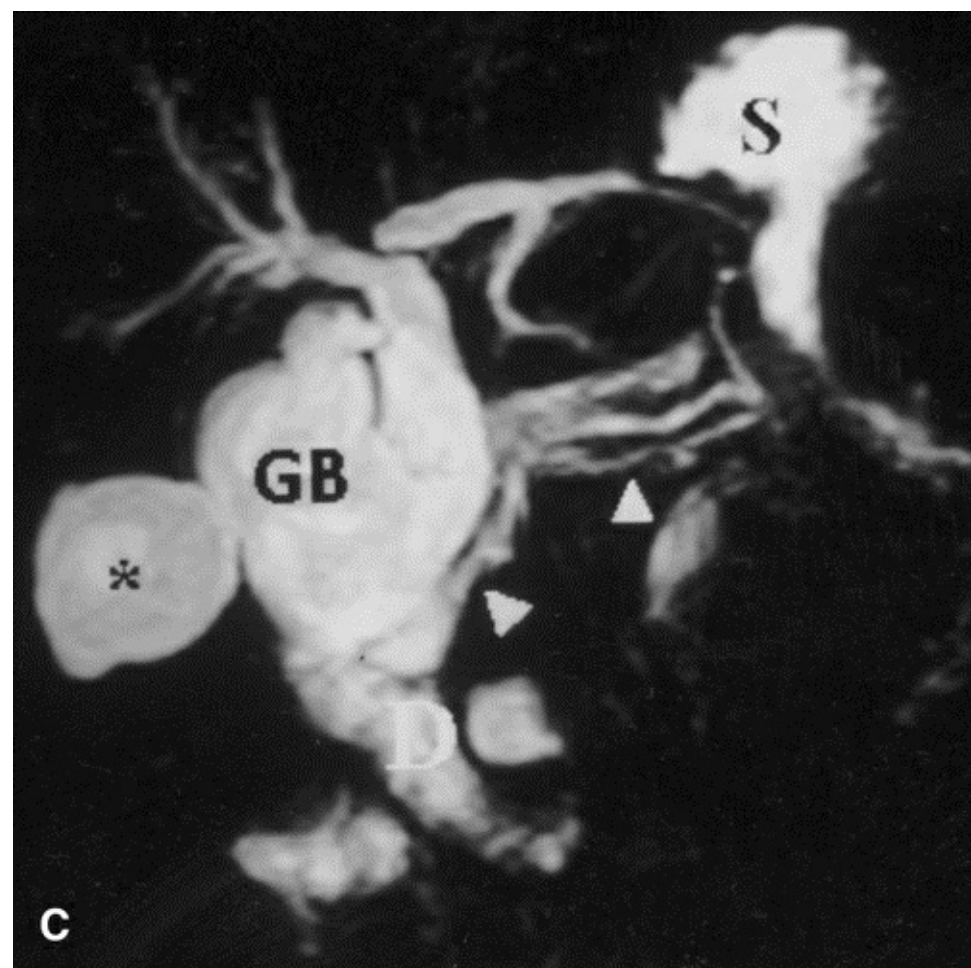


Figure 2. Continued

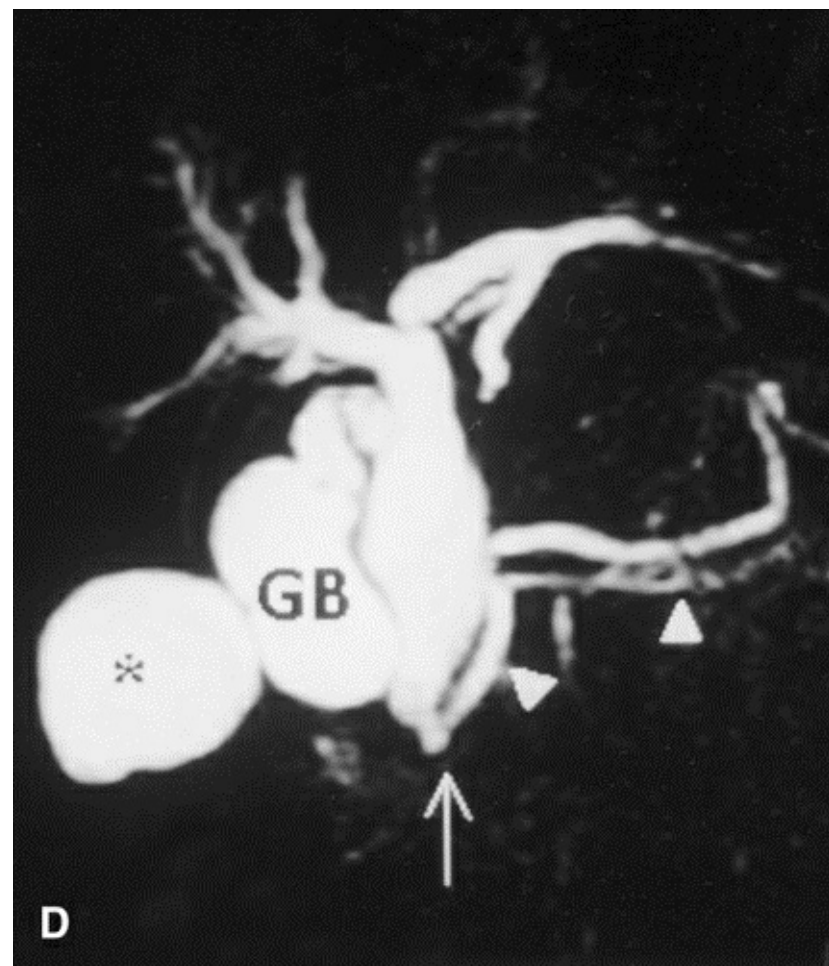


Figure 2. Continued

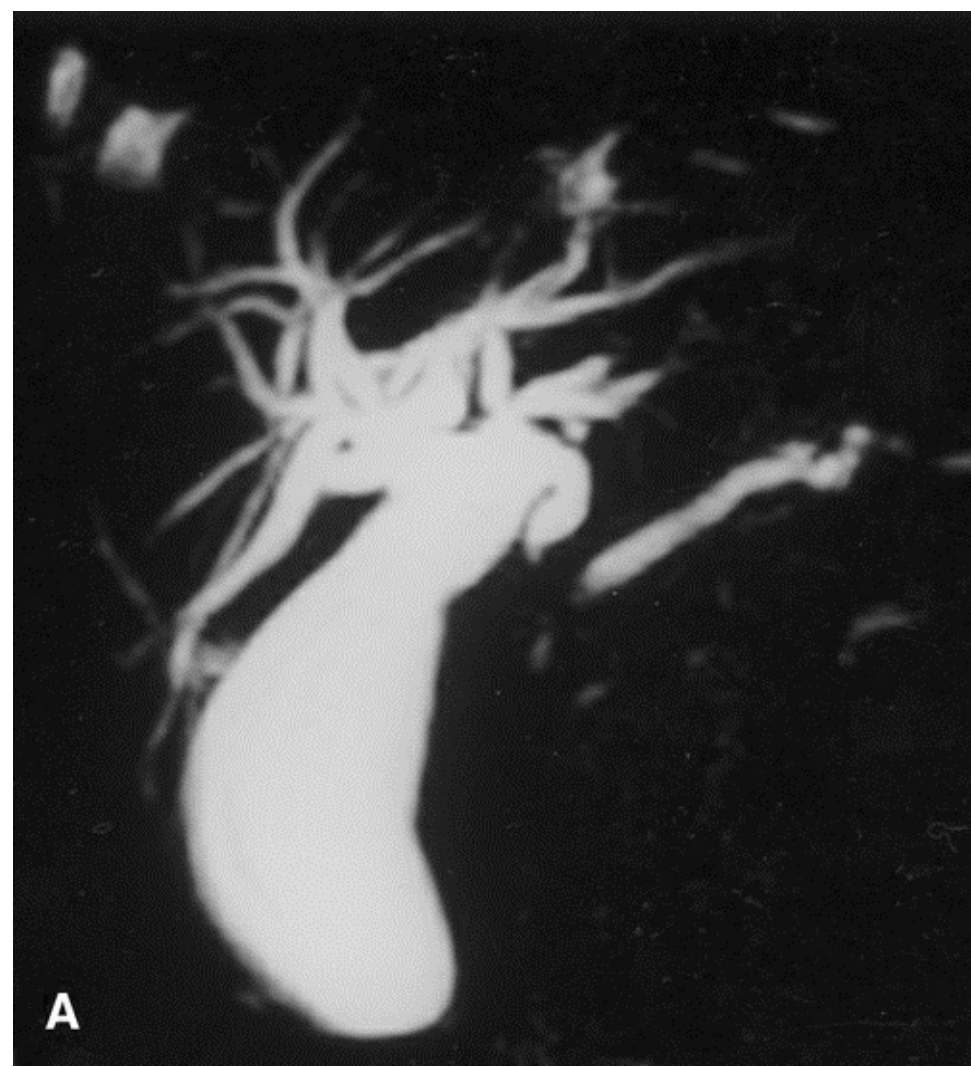

FIG. 3. Patient with a tumor in the head of the pancreas. Shown are 3D turbo spin echo maximum intensity projection image (A) before and (B) after blueberry juice administration. In B, stomach [S] and intestinal [I] signal intensities were suppressed, demonstrating the efficiency of blueberry juice in intestinal structures as well.

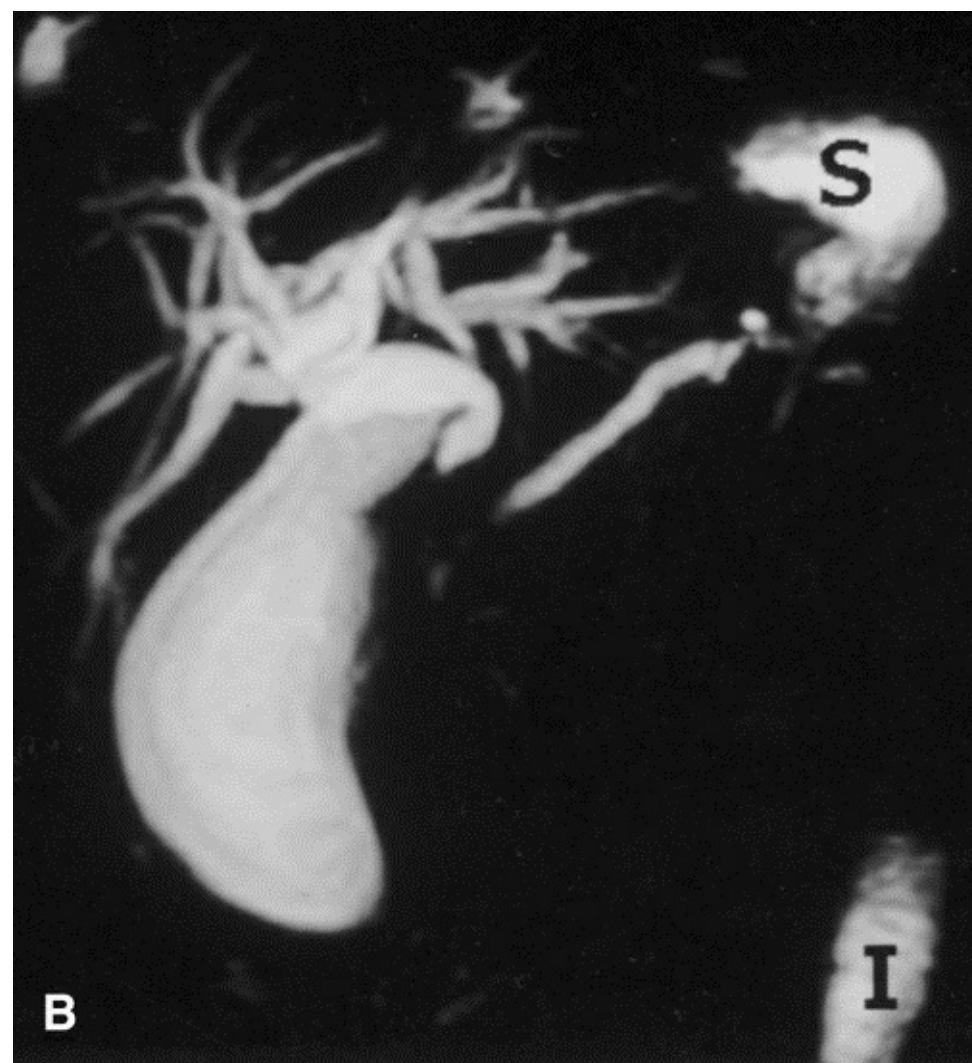


Figure 3. Continued

[Back to Top](#)

Qualitative Analysis

All source images acquired by the 3D TSE sequence were processed with a maximum intensity projection algorithm generating 15 projections at 12° intervals to produce cholangiograms. All images were reviewed independently by two reviewers who did not have any knowledge of the patient's clinical history or other imaging findings and were blinded to the presence of contrast agent. Images were displayed side by side, and the order in which the images were displayed was randomized. The reviewers were asked to record whether or not the segments of the pancreatobiliary tree were depicted by both sequences before and after the administration of blueberry juice. They graded the visualization of each segment using a 5 point scale system from 0 to 4 (0 = complete visualization—sharp edges, 1 = sufficient visualization—minor blurring, 2 = moderate visualization—moderate blurring, 3 = poor visualization—blurred borders, 4 = no visualization). The ducts that were studied included extrahepatic ducts: ampulla, common bile duct, common hepatic duct including the left-right hepatic ducts; intrahepatic ducts; and pancreatic duct: head, body, and tail. Additionally, vascular overlap and image ghost artifacts were evaluated by recording the degree of vascular signal and level of artifacts using a 4 point scale (0 = complete flow void—no artifacts, 1 = mild vascular signal—minor artifacts, 2 = moderate vascular signal—moderate artifacts, 3 = marked vascular enhancement of the portal, splenic, and hepatic veins—severe artifacts).

The scores of both reviewers were averaged. In cases of disagreement by ≥ 1 points, the final choice was made by consensus. Finally, the reviewers were asked to record the degree of dilatation of the extrahepatic bile duct using a 4 point scale (normal, mild, moderate, and severe). The same measurements were done with endoscopic retrograde cholangiopancreatography examination, and the results were compared.

[Back to Top](#)

Quantitative Analysis

The quantitative comparison included calculation of signal-to-noise ratio of the common bile duct, main pancreatic duct, gallbladder, duodenum, and liver. Signal intensity was measured by using an elliptical region of interest on the system console, whereas noise represented the standard deviation of a measurement made by placing an elliptical region of interest 2 cm anteriorly from the abdominal wall (air). Contrast-to-noise ratios between common bile duct and duodenum, common bile duct and liver, and gallbladder and liver were calculated.

[Back to Top](#)

Statistical Analysis

Statistical data analysis was based on paired Student *t* test to determine statistically significant differences in signal-to-noise and contrast-to-noise ratios between pre-and post-blueberry juice sequences. Nonparametric Wilcoxon matched pairs signed ranks and Mann-Whitney tests were used to assess if blueberry juice administration provided statistically significant improvements in the image quality of 3D TSE RT and SSTSE MRCP studies by means of improving the conspicuity of various segments of the pancreaticobiliary tree. We considered $p < 0.05$ as a valid threshold for statistical significance.

[Back to Top](#)

RESULTS

Blueberry Juice Contents

The mean \pm SD concentrations of the ions found in the contents of the three cans were 3.3 ± 0.4 $\mu\text{g/g}$ for iron and 20.6 ± 2.6 $\mu\text{g/g}$ for manganese. The total manganese and iron doses for the patients were 8.17 and 1.32 mg, respectively.

[Back to Top](#)

Qualitative Comparison

Blueberry juice administration demonstrated a statistically significant improvement in the depiction of ampulla, common bile duct, common hepatic duct, and main pancreatic duct only for the SSTSE BH sequence ($p < 0.05$). The intrahepatic bile duct demonstrated a statistically nonsignificant difference between pre-and post-blueberry juice administration for both sequences. Depiction rates and subjective grading mean values of the pancreaticobiliary segments are shown in [Table 2](#).

Blueberry juice administration demonstrated a statistically nonsignificant difference in vascular enhancement for both sequences, whereas in post-blueberry juice sequences, the ghost artifacts level was significantly reduced ($p < 0.01$). The signal intensity of duodenum was decreased statistically significantly ($p < 0.01$) in post-blueberry juice sequences, avoiding overlap with the common bile duct. Moreover, an increase in the signal intensity of the common bile duct was shown in 29 of 37 cases (78.37%) and in 9 of 16 cases (56.25%) of the main pancreatic duct for the SSTSE sequence after blueberry juice administration due to image scaling effects.

	3D TSE pre BJ	SSTSE pre BJ	3D TSE post BJ	SSTSE post BJ
Ampulla	28/33 (2.1 ± 1.1)	28/33 (2.0 ± 1.3)	31/32 (1.9 ± 1.1)	32/33 (1.4 ± 1.3)
CBD	36/37 (1.3 ± 0.9)	36/37 (1.2 ± 1.0)	36/36 (1.2 ± 0.8)	37/37 (0.8 ± 0.9)
CHD	37/37 (1.3 ± 0.9)	37/37 (1.3 ± 1.0)	37/37 (1.2 ± 1.1)	37/37 (0.9 ± 1.1)
IHD	35/37 (1.7 ± 0.9)	35/37 (1.3 ± 0.9)	34/36 (1.9 ± 0.8)	35/37 (1.3 ± 1.0)
MPD-H	21/36 (2.4 ± 1.2)	23/36 (2.3 ± 1.1)	22/35 (2.3 ± 1.3)	34/36 (1.4 ± 1.2)
MPD-B	14/37 (2.7 ± 1.0)	22/37 (2.3 ± 1.2)	14/36 (2.6 ± 1.1)	32/37 (1.4 ± 1.1)
MPD-T	5/37 (3.1 ± 0.8)	12/37 (2.7 ± 1.0)	9/36 (2.9 ± 0.9)	26/37 (1.9 ± 1.2)

Numbers in parentheses are means ± SD and refer to subjective grading. TSE, turbo spin echo; BJ, blueberry juice; SSTSE, single shot turbo spin echo; CBD, common bile duct; CHD, common hepatic duct; IHD, intrahepatic duct; MPD-H, -B, and -T, main pancreatic duct of head, body, and tail.

TABLE 2. Depiction rates of biliary and pancreatic ducts. Numbers in parentheses are means ± SD and refer to subjective grading. TSE, turbo spin echo; BJ, blueberry juice; SSTSE, single shot turbo spin echo; CBD, common bile duct; CHD, common hepatic duct; IHD, intrahepatic duct; MPD-H, -B, and -T, main pancreatic duct of head, body, and tail.

[Back to Top](#)

Quantitative Comparison

All quantitative comparison results between pre-and post-blueberry juice administration were not significantly different except mean contrast-to-noise ratio between the common bile duct and duodenum for 3D TSE RT and SSTSE BH sequences ([Table 3](#); $p < 0.01$) and mean signal-to-noise ratio of the duodenum ([Table 3](#); $p << 0.01$).

	3D TSE pre BJ	SSTSE pre BJ	3D TSE post BJ	SSTSE post BJ
SNR_{CBD}	72.62 ± 31.86	61.5 ± 50	77.73 ± 39.09	82.61 ± 66.39
SNR_{MPD}	49.07 ± 19.83	34.64 ± 44.01	53.86 ± 28.66	35.55 ± 25.18
SNR_{GB}	86.8 ± 36.64	124.2 ± 101.32	98.23 ± 51.1	175.51 ± 151.27
SNR_{LIVER}	5.27 ± 1.61	1.5 ± 0.7	6.58 ± 2.9	1.46 ± 1.18
SNR_{DUOD}	58.8 ± 37.14	54.45 ± 41.66	25.18 ± 18.85	21.54 ± 29.71
$CNR_{CBD-LIVER}$	67.35 ± 31.34	59.99 ± 49.93	71.35 ± 37.18	81.15 ± 66.28
$CNR_{CBD-DUOD}$	13.81 ± 37.25	7.04 ± 60.83	53.84 ± 35.82	61.06 ± 54.09

TSE, turbo spin echo; BJ, blueberry juice; SSTSE, single shot turbo spin echo; CBD, common bile duct; MPD, main pancreatic duct; GB, gallbladder; DUOD, duodenum.

[Back to Top](#)

DISCUSSION

Oral magnetic particles have been used in MRCP with excellent results, although they have a high cost and are not widely available at present (19). Blueberry juice was proved a very efficient negative contrast agent for suppressing the signal of the stomach and duodenum. Moreover, its administration was well tolerated by the patients; no adverse effects were recorded, using 430 ml of blueberry juice. The manganese in blueberry juice exists as a divalent ion (20). The T2 relaxation enhancement effects of blueberry juice are due to manganese (17) and iron ions. Blueberry juice reduces the intraluminal signal of the gastrointestinal tract on T2-weighted images due to the paramagnetic properties of manganese and the superparamagnetic properties of iron ions found in it. Both ions result in T2 shortening, which is responsible for signal elimination.

Hiraishi et al. (17) reported that the level of manganese in the blood of five healthy volunteers after ingestion of blueberry juice (total manganese dose 18 mg) did not change from preingestion values up to 6 h after ingestion. In another study (21), using a manganese chloride-based oral contrast agent, manganese blood levels for 18, 36, and 54 mg of total manganese dose demonstrated a slight increase 6 h after administration; these values returned to baseline levels within 24 h. In the present study, a total dose of 8.17 mg of manganese was administered to the patients, which is far lower than that of the previous studies.

Daily requirements for iron of adults are 1–2 mg/day (22). The North American diet contains between 10 and 20 mg/day, of which 5–10% is absorbed. In the present study, a total dose of only 1.32 mg of iron was administered per patient.

A lower manganese concentration was used in the present study as compared with that described by Hiraishi et al. (17) as optimal for signal suppression of the gastrointestinal tract. This may be explained by the fact that in the present study, a very long echo time was used. In Hiraishi et al. study, short echo times (70 ms) were utilized, whereas in the present study, echo time ranged from 1,000 to 1,300 ms, to achieve heavily T2-weighted contrast. Long echo times further enhance the T2-shortening effects by nulling the T1-shortening effects. This may be the reason why, in the present study, efficient gastrointestinal tract signal elimination was achieved with only a 1.9 mg/dl manganese concentration.

The administration of a negative contrast agent further reduced the ghost artifacts due mainly to bowel motion, thus resulting in higher conspicuity of the pancreatobiliary tree. Qualitative and quantitative comparison between 3D TSE RT and SSTSE BH before and after blueberry juice administration showed that blueberry juice caused a statistically significant improvement in the image quality, mainly in SSTSE sequences. Ampulla and MPD visualization was improved in post-blueberry juice SSTSE BH. The signal-to-noise ratio of duodenum was statistically significantly reduced for both sequences after blueberry juice administration, whereas the contrast-to-noise ratio between the common bile duct and duodenum was significantly higher after blueberry juice administration for both sequences.

The main drawback of the present study and of other studies using negative (in general) contrast

agents in the gastrointestinal tract is the inability to depict the exact entry point of the common bile duct and main pancreatic duct to the duodenum. However, in the particular clinical case in which the Oddi sphincter must be studied, we can alternatively administer 300 ml of water and repeat the MRCP examination. On the contrary, other investigators (23,24) reported the following as pitfalls of MRCP: (a) the presence of a duodenal diverticulum, which can distort the perampullary anatomy, giving the impression of a mass; and (b) the overlap between gastric fluid and the pancreatic duct, which can lead erroneously to a diagnosis of fluid within an ectatic, irregular pancreatic duct involved by chronic pancreatitis. Both pitfalls can be avoided by using blueberry juice.

In summary, we suggest that oral administration of blueberry juice could be used for further improvement of image quality, especially for SSTSE projectional sequences. Moreover, it can reduce the motion artifacts in 3D TSE RT sequences. Blueberry juice proved to be a new, safe, and inexpensive negative oral contrast agent for the gastrointestinal tract in MRCP.

[Back to Top](#)

Acknowledgment:

Technical assistance by E. Lavdas, R.T., V. Ftikas, R.T., A. Lytrokapis, R.T., and A. H. Zibis, M.D., is greatly appreciated.

[Back to Top](#)

REFERENCES

1. Reinhold C, Bret PM. MR cholangiopancreatography. *Abdom Imag* 1996; 21:105–16.

[Cited Here...](#)

2. Guibaud L, Bret MP, Reinhold C, Atri M, Barkun ANG. Diagnosis of choledocholithiasis: value of MR cholangiography. *AJR* 1994; 163:847–50.

[Cited Here...](#)

3. Ishizaki Y, Wakayama T, Okada Y, Kobayashi T. Magnetic resonance cholangiography for evaluation of obstructive jaundice. *Am J Gastroenterol* 1993; 88:2072–7.

[Cited Here...](#)

4. Reuther G, Kiefer B, Tuchmann A, Pesendorfer FX. Imaging findings of pancreaticobiliary duct diseases with single-shot MR cholangiopancreatography. *AJR* 1997; 168:453–9.

[Cited Here...](#)

5. Laubenberger J, Buchert M, Scneider B, Blum U, Hennig J, Langer M. Breath-hold projection magnetic resonance cholangiopancreatography (MRCP). *Magn Res Med* 1995; 33:18–23.

[Cited Here...](#)

6. Fulcher AS, Turner MA, Capps GW, Zfass AM, Baker KM. Half-Fourier RARE MR cholangiopancreatography: experience in 300 subjects. *Radiology* 1998; 207:21–32.

[Cited Here...](#)

7. Holzkecht N, Ganger J, Sackmann M, et al. Breath-hold MR cholangiography with snapshot techniques: prospective comparison with endoscopic retrograde cholangiography. *Radiology* 1998; 206:657–64.

[Cited Here...](#)

8. Barish MA, Yucel EK, Soto JA, Chuttani R, Ferrucci JT. MR cholangiopancreatography: efficacy of

three-dimensional turbo spin-echo technique. *AJR* 1995; 165:295–300.

[Cited Here...](#)

9. Ernst O, Calvo M, Sergent G, Mizrahi D, Carpentier F. Breath-hold MR cholangiopancreatography using a HASTE sequence: comparison of single-slice and multislice acquisition techniques. *AJR* 1997; 169:1304–6.

[Cited Here...](#)

10. Hirohashi S, Hirohashi R, Uchida H, et al. MR cholangiopancreatography and MR urography: improved enhancement with a negative oral contrast agent. *Radiology* 1997; 203:281–5.

[Cited Here...](#)

11. Hirohashi S, Uchida H, Yoshikawa K, et al. Large scale clinical evaluation of bowel contrast agent containing ferric ammonium citrate in MRI. *Magn Res Imag* 1994; 12:837–46.

[Cited Here...](#)

12. Li KCP, Ang PCG, Tart RP, Storum BL, Rolfes R, Ho-Tai PCK. Paramagnetic oil emulsions as oral contrast agents. *Magn Res Imag* 1990; 8:589–98.

[Cited Here...](#)

13. Tart RP, Li KCP, Storm BL, Rolfes RJ, Ang PGP. Enteric MRI contrast agents: comparative study of five potential agents in humans. *Magn Res Imag* 1991; 9:559–68.

[Cited Here...](#)

14. Rinck PA, Smevik O, Nilsen G, et al. Oral magnetic particles in MR imaging of the abdomen and pelvis. *Radiology* 1991; 178:775–9.

[Cited Here...](#)

15. Brown JJ, Duncan JR, Heiken JP, et al. Perfluorooctylbromide as a gastrointestinal contrast agent for MR imaging: use with and without glucagon. *Radiology* 1991; 181:455–60.

[Cited Here...](#)

16. Mitchell DG, Vinitzki S, Mohamed FB, Mammone JF, Haidet K, Rifkin MD. Comparison of Kaopectate with barium for negative and positive enteric contrast at MR imaging. *Radiology* 1991; 181:475–80.

[Cited Here...](#)

17. Hiraishi K, Narabayashi I, Fujita O, et al. Blueberry juice: preliminary evaluation as an oral contrast agent in gastrointestinal MR imaging. *Radiology* 1995; 194:119–23.

[Cited Here...](#)

18. Challa A, Papaefstathiou I, Lapatsanis D, Tsolas O. Primary idiopathic hypomagnesemia in two female siblings. *Acta Paediatr* 1995; 84:1075–8.

[Cited Here...](#)

19. Matos C, Metens T, Deviere J, et al. Pancreatic duct: morphologic and functional evaluation with dynamic MR pancreatography after secretin stimulation. *Radiology* 1997; 203:435–41.

[Cited Here...](#)

20. Yamamoto Y, Hasegawa H. Components of oral contrast agents for magnetic resonance imaging [Japanese]. *Food Ingrid J* 1993; 158:102–19.

[Cited Here...](#)

21. Bernardino ME, Weinreb JC, Mitchell DG, William SC, Morris M. Safety and optimum concentration of a manganese chloride based oral MR contrast agent. *J Magn Res Imag* 1994; 4:872–6.

[Cited Here...](#)

22. Schreiber WE. Iron, porphyrin and bilirubin metabolism. In: Kaplan LA, Pesce AJ, eds. *Clinical chemistry: theory, analysis and correlation*. St. Louis: Mosby, 1989: 496–511.

[Cited Here...](#)

23. David V, Reinhold C, Hochman M, et al. Pitfalls in the interpretation of MR

cholangiopancreatography. AJR 1998; 170:1055–9.

[Cited Here...](#)

24. Fulcher AS, Turner MA. Pitfalls of MR cholangiopancreatography. J Comput Assist Tomogr 1998; 22:845–50.

[Cited Here...](#)

Index Terms: Magnetic resonance imaging; Bile ducts; Cholangiography; Contrast medium

© 2000 Lippincott Williams & Wilkins, Inc.