

Case Report

X-ray turns a blind eye to ferrous metal

Brendan JT Vote MBBS and Allan J Simpson FRACO

Department of Ophthalmology, Christchurch Public Hospital, Christchurch, New Zealand

ABSTRACT

The case is reported of a 31-year-old man with a retained metallic intraocular foreign body (IOFB) in the left eye who underwent magnetic resonance imaging (MRI) for investigation of a subsequent unrelated brachial plexus injury. Despite the patient providing good history of IOFB, the decision to proceed with MRI was based on screening orbit X-ray which was reported as normal. A review of published reports regarding screening recommendations for MRI for patients with IOFB is provided. A minimum recommendation is for prescreening questionnaire; belief of the patient history is critical. If there is any doubt after history and examination by an ophthalmologist, then computed tomography imaging of the orbits is recommended. Whether screening by plain X-ray imaging is worthwhile is debatable as the sensitivity and specificity of this modality is poor.

Key words: magnetic resonance imaging, metallic foreign body, traumatic cataract.

CASE REPORT

A 31-year-old healthy man with no past ocular history presented acutely with a history of hammering metal on metal. At initial presentation, unaided visual acuity was 6/5 right eye and 6/6 left eye. A left visual-axis corneal-perforating wound was noted with corresponding anterior lens penetration and a 'metallic' intraocular foreign body (IOFB) under the anterior lens capsule centrally. The corneal wound was seidel negative, there was no lens opacity and remaining examination was normal. Regular follow up revealed stable visual acuity of 6/5 in the left eye and no further complications.

Four months after his ocular injury, the patient was involved in a motorcycle accident. He was investigated with an magnetic resonance imaging (MRI) scan for brachial plexus injury, despite stating that he had a left metallic IOFB. A plain orbit X-ray obtained before the MRI was reported as normal; however, a metallic IOFB is apparent on

re-inspection (Fig. 1). Prior to the MRI the patient considered his vision in the left eye normal. Subsequent to his MRI the IOFB shifted inferiorly and the patient developed gradual but marked progression of cataract over months (Fig. 2a). He underwent cataract extraction and intraocular lens insertion, obtaining corrected visual acuity of 6/5. Figure 2b shows the IOFB after removal.

DISCUSSION

Ocular injuries occur commonly in the general population, with retained metallic IOFB associated with metalworking the most frequent type of serious ocular trauma.¹ Kelly *et al.* first reported a serious ocular complication (vitreous haemorrhage and unilateral blindness) related to MRI of a patient with a clinically occult intraocular metallic foreign body.² Recently, hyphaema has been reported,³ although more serious hazards have been reported including death in a patient with an intracerebral aneurysm clip imaged by MRI.⁴

Many studies have been conducted to assess the potential risk of MRI.^{1,5–10} Many early studies used much weaker magnets⁷ than those commonly used in clinical practice (1.5 Tesla in the present case). Most centres follow the guidelines of the Safety in MRI report of 1991.¹¹ Boutin *et al.* surveyed 207 academic institutions in the United States (99% response rate) looking at the methods used for identifying patients who might have metallic foreign bodies or other contraindications to MRI.¹ Screening methods included written questionnaire (93%), plain film orbits (85%), computed tomography (CT) orbits (41%) or metal detector (12%). Though no injuries related to intraorbital foreign bodies were reported, there was a lack of consensus on screening protocols before MRI. They recommended a minimum screening by written questionnaire followed by oral questioning to determine those at risk. It was noted that 5% of centres used no radiographic screening prior to MRI.

In a subsequent study, Williamson *et al.* attempted to measure the prevalence of metallic foreign bodies in the orbits of 15 024 patients scheduled for MRI during a 4-year period and to determine if screening by plain radiography, CT or both before MRI was useful.⁵ Eleven per cent (1593)

■ Correspondence: Dr Brendan JT Vote, Department of Ophthalmology, Auckland Public Hospital, Private Bag, Auckland, New Zealand.

Email: eye.vote@clear.net.nz

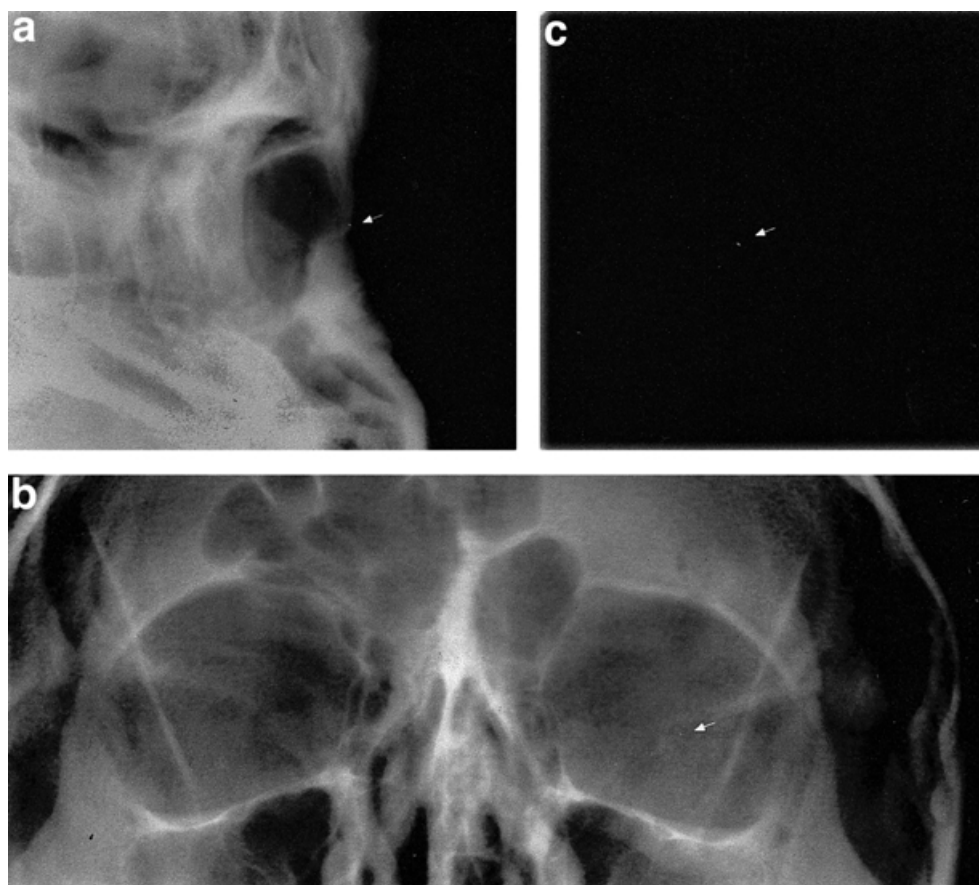


Figure 1. (a,b) Preoperative X-ray. Reported as no evidence of intraocular foreign body; however, closer inspection does show evidence of a metallic intraocular foreign body (→). (c) The radiological appearance is better appreciated when the intraocular foreign body is viewed as imaged by X-ray after its removal from the eye.

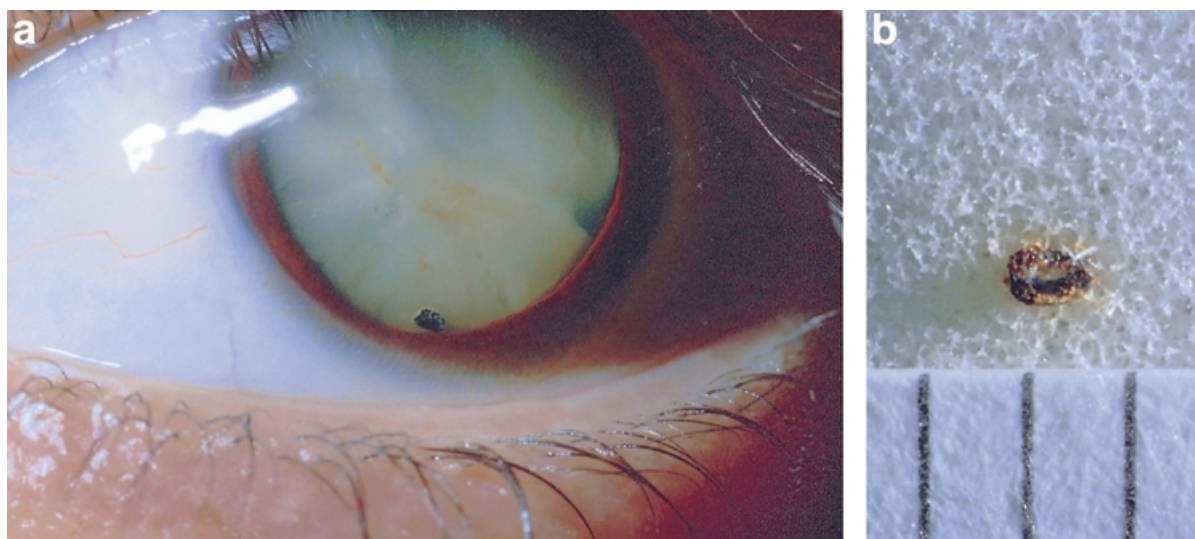


Figure 2. (a) Preoperative photograph showing metallic foreign body at inferior dilated pupil margin. The foreign body location at original presentation is evident as a rust mark just below the centre of the pupil. (b) Photograph of intraocular foreign body after its removal from the eye. Note evidence of corrosion indicating ferrous composition. Scale is millimetres, therefore size is approximately 1 mm.

of patients identified themselves at risk of intraocular metallic foreign body. Metallic foreign bodies were discovered in 40 patients including two patients who did not identify themselves at risk and underwent MRI before the metal was detected, without adverse effect. The prevalence of metallic

IOFB was low in their study (0.27%), even in those patients identified as at risk (2.5%). Based on these data they extrapolated that more than 2400 patients with intraorbital metallic foreign bodies had undergone magnetic resonance imaging between 1986 and 1993 without report of injury.

They inferred that the risk of eye damage for patients with metallic IOFB was low and that radiographic screening before imaging was not needed as often as it was done. Williams *et al.* used a rabbit model to examine the consequences of MRI in the presence of ferromagnetic foreign bodies in various orbital and intraocular locations.⁶ They concluded that in the absence of ocular symptoms and with negative AP and lateral orbital X-rays, MRI can be safely performed without intraocular or orbital damage.

Furthermore, Bray and Griffiths concluded that in the absence of evidence of penetrating injury, screening by plain radiography in suspected metallic IOFB was inappropriate as the true positive rate is too low and the false negative rate too high for this to be effectively performed.¹² Bryden *et al.* compared real time B-scan ultrasound with X-ray and found that careful (gentle) ultrasound was significantly better at detecting all types of IOFB (93%) compared with X-ray which detected only 40% of IOFB (and only 69% for metallic IOFB), and approaches the level of CT detection.¹³ Another study found that CT detected all IOFB with the exception of intraocular lenses.⁸ More importantly, however, Bray and Griffiths found that in no case was an IOFB detected on X-ray without concomitant evidence of ocular penetration.¹² A clinical examination by a competent ophthalmologist was considered the most important investigation.

It is interesting to speculate that the present patient developed cataract as a result of MRI performed in the presence of a metallic IOFB. Clearly his primary injury with retention of intralenticular foreign body is sufficient to explain a traumatic cataract.¹⁴ However, significant progression occurred only after the MRI was performed and not for 4 months beforehand. What is more interesting, however, is the fact that plain X-ray reporting on two occasions did not detect the metallic IOFB (including retrospective analysis with history) and thus cannot be relied upon as an adequate single screening tool prior to MRI.

A minimum recommendation is for a prescreening questionnaire, not just for history of ocular trauma but also for at-risk occupations or hobbies (e.g. metal workers). Belief of the patient history is critical. If there is any doubt after history and examination by an ophthalmologist then CT imaging of the orbits (or alternately gentle B-scan ultrasound) is recommended. Whether screening by plain film X-ray imaging is worthwhile is debatable as the sensitivity and specificity of this modality is poor.

REFERENCES

1. Boutin RD, Briggs JE, Williamson MR. Injuries associated with magnetic resonance imaging: survey of safety records and methods used to screen patients for metallic foreign bodies before imaging. *Am. J. Roentgenol.* 1994; **162**: 189–94.
2. Kelly E, Paglen PG, Pearson JA, San Diego AC, Solomon MA. Ferromagnetism of intraocular foreign body causes unilateral blindness after magnetic resonance study. *Am. J. Neuroradiol.* 1986; **7**: 243–5.
3. Ta CN, Bowman RW. Hyphaema caused by a metallic foreign body during magnetic resonance imaging. *Am. J. Ophthalmol.* 2000; **129**: 533–4.
4. Klucznik RP, Carrier DA, Pyka R, Haid RW. Placement of a ferromagnetic intracerebral clip in a magnetic field with fatal outcome. *Radiology* 1993; **187**: 855–6.
5. Williamson MR, Espinosa MC, Boutin RD, Orrison Jr WW, Hart BL, Kelsey CA. Metallic foreign bodies in the orbits of patients undergoing magnetic resonance imaging: prevalence and value of radiography and CT before magnetic resonance. *Am. J. Roentgenol.* 1994; **162**: 981–3.
6. Williams S, Char DH, Dillon WP, Lincoff N, Moseley M. Ferrous intraocular foreign bodies and magnetic resonance imaging. *Am. J. Ophthalmol.* 1988; **105**: 398–401.
7. Kelsey CA, King JN, Keck GM, Chiu MT, Wolfe DM, Orrison WW. Ocular hazard of metallic fragments during magnetic resonance imaging at 0.06 T. *Radiology* 1991; **180**: 282–3.
8. Guneric U, Maden A, Kaynak S, Pimar T. Magnetic resonance imaging and computed tomography in the detection and localisation of intraocular foreign bodies. *Doc. Ophthalmol.* 1992; **81**: 369–78.
9. Lagouros PA, Langer BG, Peyman GA, Mafee MF, Spigos DG, Grisolano J. Magnetic resonance imaging and intraocular foreign bodies. *Arch. Ophthalmol.* 1987; **105**: 551–3.
10. Williamson TH, Smith FW, Forrester JV. Magnetic resonance imaging of intraocular foreign bodies. *Br. J. Ophthalmol.* 1989; **73**: 555–8.
11. Shellock FG, Kanal E. SMRI report: policies, guidelines and recommendations for magnetic resonance imaging safety and patient management. *J. Magn. Reson. Imaging* 1991; **1**: 97–101.
12. Bray LC, Griffiths PG. The value of plain radiography in suspected intraocular foreign body. *Eye* 1991; **5**: 751–4.
13. Bryden FM, Pyott AA, Bailey M, McGhee CNJ. Real time ultrasound in the assessment of intraocular foreign body. *Eye* 1990; **4**: 727–31.
14. Streeten BW. Pathology of the lens. In: Albert DM, Jacobiec FA (eds) *Principles and Practice of Ophthalmology*, Vol. 4. Philadelphia: WB Saunders, 1994; 2007–8.

Copyright of Clinical & Experimental Ophthalmology is the property of Wiley-Blackwell and its content may not be copied or emailed to multiple sites or posted to a listserv without the copyright holder's express written permission. However, users may print, download, or email articles for individual use.