

## Dorsal rhizotomy combined with anterior sacral root stimulation for neurogenic bladder

J. R. Vignes<sup>1</sup>, L. Bauchet<sup>2</sup>, and F. Ohanna<sup>2</sup>

<sup>1</sup> Department of Neurosurgery and Neurorehabilitation of Montpellier, CHU de Montpellier, Hôpital Gui de Chauliac, Montpellier Cedex, France

<sup>2</sup> Department of Neurosurgery of Bordeaux, CHU de Bordeaux, Hôpital Pellegrin, Bordeaux Cedex, France

### Summary

A spinal cord lesion (traumatic or not) above the sacral micturition center may induce hyperreflexia of the detrusor, spasticity of the sphincter and vesico-sphincter dyssynergia. Eventually, alterations in the upper urinary tract can be associated with increased mortality in this patient population. Sacral rhizotomies combined with implantation of an anterior sacral root stimulator appear to be an effective method not only for the treatment of voiding dysfunction but also for defecation and sexual disorders. The clinical and electrophysiological checks and the surgical technique are described. In most series, the results show a constant improvement in the patient's functional status. Ninety percent of patients gain satisfactory continence and no longer require an incontinence appliance. Bladder capacity and compliance increase dramatically. As a consequence, urinary infection rate decreases. The majority of patients remain dry, and more than 80% have a complete voiding or a post-void residue of less than 50 ml and do not require any catheterization.

Anterior sacral root stimulation combined with sacral posterior rhizotomy is a valuable method to restore bladder function in spinal cord-injured patients suffering from hyperactive bladder.

**Keywords:** Neurogenic bladder; electric stimulation therapy; spinal cord injuries; spasticity; surgical procedures; rhizotomy; urinary tract infection; spinal nerve roots.

### Introduction

The National Spinal Cord Injury Association [16] estimates that 250,000–400,000 individuals living in the USA suffer from a spinal cord lesion; the incidence of spinal cord lesion is 32 lesions per million inhabitants per year; this corresponds to 7,800 new cases per annum. According to this estimation, at least 330,000 people suffer from a spinal cord lesion (paraplegia or tetraplegia) in the European Union, and approximately 11,000 new cases are recorded each year. Twenty new cases per million inhabitants per annum represent the minimum incidence in

Europe. Extrapolating the above statistics to the world population, gives an estimate of 32,000 people developing a spinal cord lesion each year. This represents more than 87 lesions per day, meaning a new lesion every 16 minutes. However, these figures are probably an underestimation, and apply to industrialized countries only. In all countries, the etiology is traumatic in nearly 80% of the cases, with a strong predominance of males; in half of the cases the spinal lesions are complete [6].

Complete lesions of the spinal cord are accompanied by a sensory-motor deficit, a major handicap for the patient, who cannot be cured in spite of research efforts in stem cells or nerve growth factors. Spasticity of spinal origin must be managed and an extensive examination must seek the underlying cause (syringomyelia, etc.). Occasionally specific treatment for spasticity may suffice (Baclofen<sup>®</sup> pump, DREZotomy, rhizotomy, etc.). Moreover, in 30–40% of the cases [7], neurogenic pain may create problems in the treatment of spinal cord-injured patients. The treatment of bladder disorders in spinal cord-injured patients must be integrated into the overall treatment plan. The “spastic bladder” is integrated in the nosologic framework outlined above, because it is among the principal complaints of patients presenting with a spinal lesion [7]. Neuro-urologic complications in the spinal cord-injured patient have, for a long time, represented the primary cause of mortality. The risk of deterioration of the upper urinary tract may occur at anytime in the life of these patients because of repeated urinary infections, vesico-ureteral reflux or hydronephrosis [22]. In suprasacral injuries, bladder dysfunction can be

dangerous to the upper urinary tract; the dysfunction is characterised by hyperactivity causing incontinence, and is often associated with vesico-sphincter dyssynergia causing incomplete voiding, and particularly high intra-vesical pressures causing reflux and dilation. A functional surgical procedure is currently proposed to the patient at risk, which preserves the anatomy of the urinary tract and restores the functions of this apparatus (bladder filling, and voluntary voiding).

### Anatomy and physiology of the lower urinary tract

The lower urinary tract has two main functions: storage and periodic voiding of urine. These two functions are regulated by a complex neural control system involving a central pathway located in the spinal cord, pons and brain and peripheral autonomic and somatic neural pathways. This control system works like a switching circuit to maintain a reciprocal relationship between the bladder and outlet components of the lower urinary tract.

The storage (Fig. 1a) and periodic voiding of urine (Fig. 1b) are dependent on the reciprocal activity of two

functional units in the lower urinary tract: a reservoir, the bladder and an outlet, i.e. the bladder neck and the smooth and striated sphincter muscles of the urethra. During urine storage, the bladder outlet is closed and the bladder smooth muscle is quiescent, allowing intravesical pressure to remain low over a wide range of bladder volumes. During voluntary voiding, the initial event is a relaxation of the pelvic floor and striated urethral muscles; this is followed by a detrusor muscle contraction and opening of the bladder neck. This activity is mediated by three sets of peripheral nerves: parasympathetic (pelvic), sympathetic (hypogastric) and somatic (pudendal) nerves. These nerves also contain afferent axons, terminating in the lower urinary tract, which are involved in initiating micturition.

### Spinal levels

#### *Efferent pathway*

The parasympathetic efferent pathway is the main excitatory input to the bladder. Parasympathetic preganglionic axons originate in the intermediolateral column of the S2–S4 spinal cord and terminate in the postganglionic neurons in the bladder wall and in the pelvic plexus. The main neurotransmitter released by the parasympathetic postganglionic nerve terminals is acetylcholine. The sympathetic preganglionic neurons are located within the intermediolateral cell column of the T11–L2 spinal cord. They make synaptic connections with postganglionic neurons in the inferior mesenteric ganglionic neurons in the paravertebral ganglia and pelvic ganglia. Sympathetic postganglionic terminals release norepinephrine which acts on alpha-1 vesical and urethral receptors and beta-2 adrenergic detrusor receptors. The effect of norepinephrine on the former is a contraction of the bladder base and urethral smooth muscle. The effect of norepinephrine on the latter, via an action of the beta 2 receptors, can also relax the bladder body.

Somatic efferent pathways that originate from the motoneurons in the Onuf nucleus of the anterior horn of the S2–S4 spinal cord innervate the external striated urethral sphincter muscle and the pelvic floor musculature. Somatic nerve terminals release acetylcholine, which acts on nicotinic receptors to induce a muscle contraction. The striated urethral sphincter also receives noradrenergic input from the sympathetic nerves. The combined activation of the sympathetic and somatic pathways elevates bladder outlet resistance and contributes to urinary continence. The striated sphincter (via the pudendal

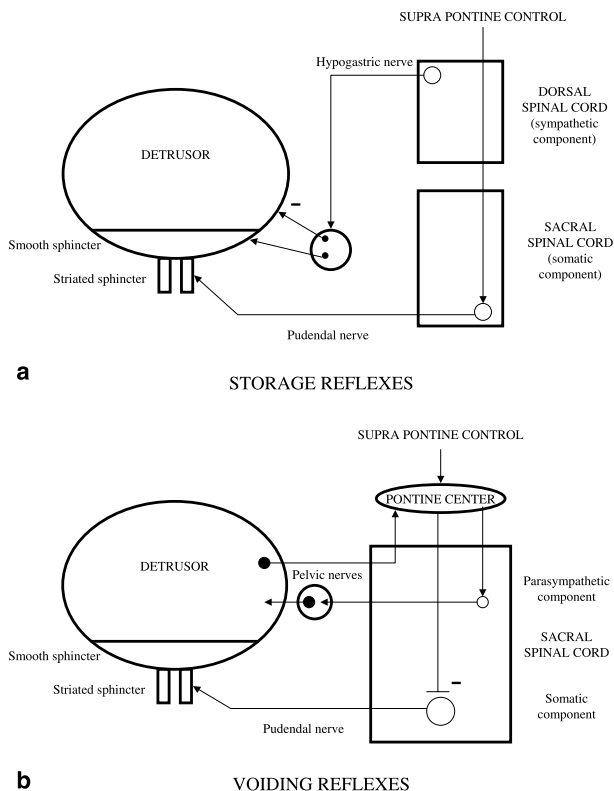


Fig. 1. Pathophysiology and neuronal network of vesico-sphincter functions Storage reflexes (a) and voiding reflexes (b)

nerve) is the unique element of voluntary continence and micturition.

#### *Afferent pathway*

Sensory information regarding bladder fullness is conveyed to the spinal cord via afferent axons in the pelvic and hypogastric nerves, which possess neuronal somata in the dorsal root ganglia at the S2–S4 and T11–L2 spinal segmental levels. Afferent fibers passing in the pelvic nerve carry impulses from tension receptors in the bladder wall to neurons in the dorsal horn of the spinal cord. These are mainly small myelinated ( $A\delta$  fibers) and unmyelinated (C fibers) axons [4]. In several mammalian species including human, the normal micturition reflex is mainly mediated by  $A\delta$  afferent fibers that respond to bladder distension. The C fibers, which have a high mechanical threshold, are usually unresponsive to bladder distension and are thus called silent C-fibers, but many of them do respond to chemical, noxious or cold stimuli.

#### *Spinal centers*

The sacral micturition center involves laminae VI, VII and X. The interneurons participate in local control of elementary programs via parasympathetic and somatic pathways [12]. The C fibers project to the dorsal horn and via a polysynaptic reflex with medullary interneurons form the «C reflex» of Bradley [4].

#### **Pontine centers**

Among the sub-encephalic centers involved in micturitional control, the most important are located in the pons. This part of the tegmentum receives afferent pathways from collateral spino-thalamic axons (from dorsal horn, laminae I and IV) to form the spino-ponto-spinal reflex or the «A reflex» of Bradley [4]. Two pontine centers have been characterized in mammals. The first is localized in the medial part of the dorsolateral pontine tegmentum, and is thus called the M-region or pontine micturitional center (PMC). The PMC projects to the sacral intermediolateral cell column, in which are located the parasympathetic center connected to the bladder motoneurons and the sacral intermediolateral cell column. The PMC is involved in the voiding phase via both these projections. The excitatory PMC projection to bladder motoneurons is responsible for an increase in bladder pressure during micturition. The relaxation of the striated urethral sphincter during micturition is due

to excitatory projection to inhibitory interneurons in the spinal dorsal gray commissure.

The second pontine center, located more ventrally and more laterally than the PMC in the pontine tegmentum, is involved in the storage of urine during continence. During the storage phase, this L-center or pontine storage center (PSC) acts by direct excitatory projection to the urethral sphincter in the nucleus of Onuf [3].

#### **Suprapontine controls**

At the mesencephalic level, the periaqueductal gray (PAG) is considered as the main center involved in micturitional control. The PAG is thought to act as a central sensorimotor integrative relay of the micturition reflex, via the reception of sensory information concerning bladder fullness and the direct projection to the PMC. In the forebrain, the most documented structure is the pre-optic area of the hypothalamus, which is thought to play a role in the initiation of the voiding phase via direct projection to the PMC. In addition, the anterior cingulate gyrus, amygdala, red nucleus of the stria terminalis and septal nuclei are susceptible, when excited, to elicit bladder contraction. The superomedial part and the superolateral part of the precentral gyrus seem to be involved in voluntary control on the pelvic floor and in abdominal straining, respectively. Finally, the exact role of the cerebellum is not fully understood, but both afferent and efferent contributions to the micturitional reflex have been proposed.

#### **Principles of the Brindley technique**

Essentially, the technique consists of triggering a micturition by acute electrostimulation of the sacral roots. However, this acute stimulation depolarizes in a non-specific way, both the fibers within the pelvic nerves, which invest the detrusor muscle, and the fibers serving the urethral striated sphincter (contained in the pudendal nerves), resulting in a dyssynergic micturition. The effective micturition is obtained by exploiting the difference in relaxation time between striated and smooth muscle fibers. The striated fibers in the sphincter cease contracting immediately when the stimulation stops whilst the smooth fibers within the detrusor continue to contract as demanded. It is thus necessary to apply an intermittent stimulation [22]. The voiding of urine is thus obtained after several pulses of stimulation of 300 milliseconds with a frequency of 30 Hertz [6] (Fig. 2). The possibility of selectively stimulating parasympathetic

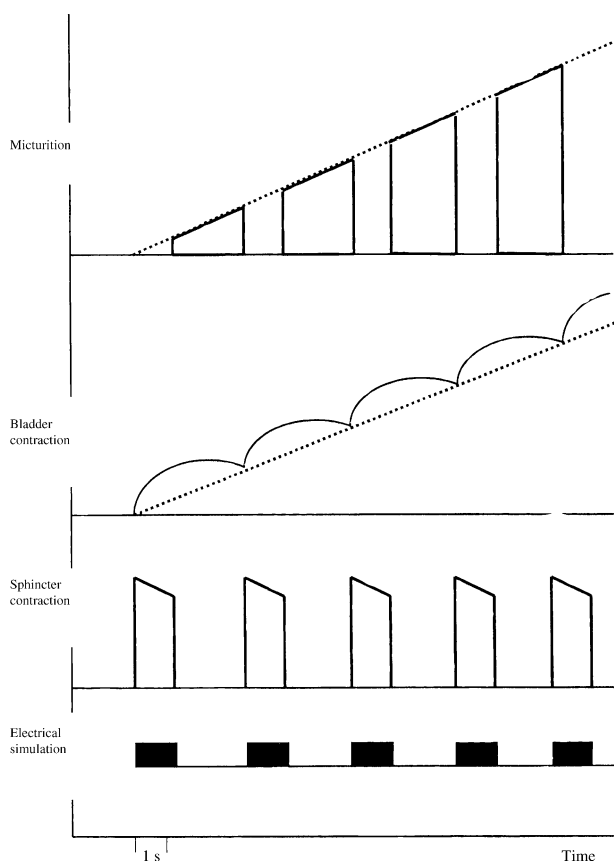


Fig. 2. The micturition by intermittent electrical stimulation is illustrated in this schematic representation. Micturition occurs during the gap at the end of each burst of impulses. The number of bursts delivered (approximately 4–10 to empty the bladder) varies according to the urinary volume, the degree of electrically induced detrusor-sphincter dyssynergia and the contracting ability of the detrusor

detrusor fibers is currently being researched. Others have described the possibility of blocking fibers investing the sphincter during stimulation. However, detrusor and sphincter hyperreflexia prevent continence and do not allow complete and effective micturition [6]. It is thus imperative to perform deafferentation of the sacral center of micturition by performing rhizotomies of the posterior sacral roots and thus create a true sacral deafferented bladder. Thus, the spinal micturitional reflex is abolished, avoiding any resulting detrusor contraction through stimulation of its baroreceptors. In the same way, the striated urethral sphincter no longer contracts under the influence of the peripheral afferent pathways [5].

### Indications

The technique is aimed at patients who are para- or complete tetraplegics, bearing a medullar lesion located over the sacral urinary centres. These patients present

with a non-stabilised hyperactive bladder (central bladder) and have experienced, in the main, failure with re-education methods. The best indication is the patient presenting with uncontrolled leaks, on a non-disinhibited bladder, at weak capacity, and with or without vesico-sphincter dyssynergia [11]. Patients conserving a sensitive saving may perhaps benefit from the technique if they present bladder hyperactivity responsible for uncontrolled leaks, with chronic urinary retention being a source of severe infections and a threat to the upper urinary tract. The issues of assisting defecation and obtaining programmed erections in the male, are rarely held in prime consideration [5]. The technique, therefore, is directed to complete spinal cord injury sufferers presenting with a supra-sacral lesion. At present, this indication is met when a hyperactive bladder is the source of incontinence (associated or not with dyssynergia) and a risk to the upper tract, and this bladder hyperactivity cannot be corrected by traditional re-educative techniques (intermittent catheterizations and anticholinergics). The indications of Brindley technique can be described as follows:

- In paraplegic women not managed by the combination of self-catheterisations and anticholinergics.
- In tetraplegic women, the indication should be discussed with criteria the patient's dependence and third party interests. In low cervical lesions, self-catheterisation is often possible, but it is difficult and time-consuming, making the technique debatable. In middle cervical tetraplegias (C6), perineal self-catheterisation is not functional and not often considered; the choice should be made between the Brindley technique and continent cystostomy. Above C5, there are few alternatives apart from Bricker's non-continent diversion which requires collection pockets and human assistance 4 times a day (transfers, dressing) to assist urination (fewer complications and maintenance of body image). Finally, techniques of muscular-tendinous reanimation of the upper limbs can improve patients' quality of life (better handling of the stimulator).
- In paraplegic men, indications are found in the same conditions, but we must take into account the genitosexual status (disappearance of reflex erections and reflex ejaculations). In fact, although in studies, more than 50% of spinal cord-lesioned patients have erections, they are mostly insufficient for penetration or last for a short time (unstable). Brindley technique is particularly indicated in paraplegic men without satisfactory reflex erection. Furthermore, after implantation, restoration of an erection remains possible by

having Brindley's specific programme, or intra-cavernous injections.

- In tetraplegic men, the Brindley technique should be put in the balance with the sphincterotomy and the choice should be made based on criteria of dependence and continence. The technique is also efficient in controlling autonomous hyperreflexia phenomena, and therefore, the existence of such phenomena will be determining the choice of treatment.

## Material

The "Finetech-Brindley Bladder controller system" consists of an implantable receiver, which stimulates the sacral roots, and an external transmitter which is used to program the various parameters of stimulation. The implantable components consist of electrodes terminating in root traps, into which the appropriate sacral nerves are placed. The electrodes are connected by cables to a receiver-stimulator which is encased in silicone and implanted under the skin. The external material consists of an antenna connected to an external transmitter/controller device which allows programming of the stimulation parameters (frequency, duration, intensity), and provides the energy (by radio frequency coupling between antenna and receiver) for root stimulation (Fig. 3). For patient treatment, three different programs exist: I for micturition, II for defecation, and III for erection.

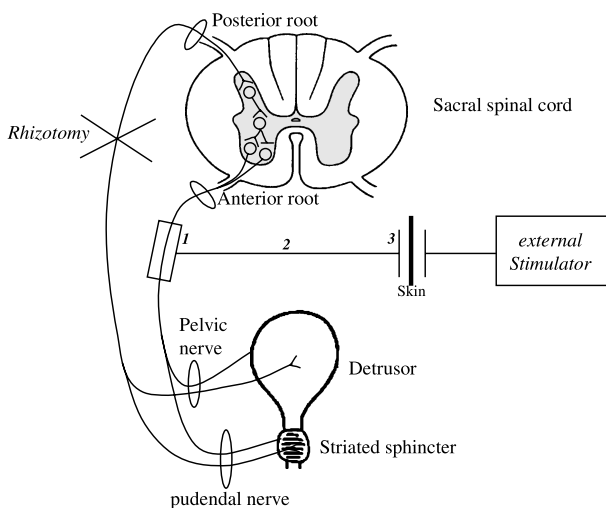


Fig. 3. Principle of the Brindley method. Electrical stimulation of the sacral anterior roots induces a "voluntary" and functional micturition. Posterior rhizotomies (S2-S4) suppress the vesicosphincter hyperreflexia, enhance continence and reduce dysautonomia symptoms. (1) electrodes, (2) cables, (3) a receiver-stimulator encased in silicone which is implanted under the skin

## Surgical methods

The goal of Brindley technique is to realise a complete sacral deafferentation of the bladder and to connect sacral anterior roots with electrodes for electrical stimulation. Currently, we describe three methods (intradural, extradural, or sacral technique). The intradural method was introduced by Brindley in the seventies [5].

### Intradural approach

Surgical intervention implies a lumbo-sacral stage of fixing the electrodes and a thoracic stage for implantation of the radio-receiver. The patient is operated on under general anaesthesia avoiding drugs that interfere with bladder contraction; curares and anticholinergics such as atropine would reduce the vesical responses to stimulation. The patient should be warmed to between 36 and 37 °C in order to avoid the influence of hypothermia on the autonomic nervous system. Hemodynamic monitoring (blood pressure, cardiac rate) is routinely performed. More recently, a specific, non-invasive marker of the autonomic nervous system (spectral analysis of the ECG) has been proposed for the early detection of reactional autonomous hyperreflexia. The patient is placed in ventral decubitus position with genupectoral support, in such a way as to leave free the perineal region and the lower limbs, for intraoperative monitoring. The horse-tail roots are exposed intradurally, after a laminectomy




Fig. 4. Microphotograph of anterior roots placed into the 3-channel intradural implant slots. The 3-channel implant is composed of 2 electrode books. The upper book contains 3 parallel slots laterally for each (right or left) anterior S2 root and medially for both (right and left) anterior S3 roots. The lower book contains 1 slot for anterior S4 or S4-S5 roots. There are three electrodes in each slot (1 cathode in the centre and 2 anodes at the ends) to avoid stimulation of unwanted structures. Anterior roots of S2 (thick arrows); anterior roots of S3 (thin arrows); anterior roots of S4-S5 (arrowhead); right cut posterior root of S2 (star); right cut posterior root of S3 (asterisk)

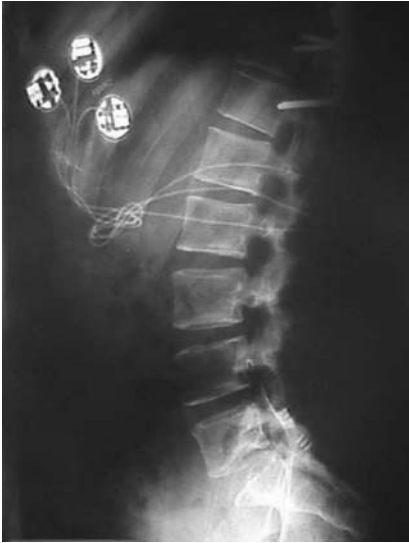

Fig. 5. Postoperative X-rays of an implanted patient. Note the osteosynthesis of the spine for T10 fracture responsible of paraplegia

reaching L3 and spreading along the sacrum roof (respecting the articular joints to avoid rachidian destabilisation). The stage of identification of roots is important, and is generally carried out with an operative microscope. Electrical stimulations are applied to the S2–S5 sacral roots to identify the motor and sensory parts and above all to identify by cystomanometric control which roots are involved in bladder function. Contraction of the buttocks and soleus muscle corresponds to level S2, that of the pelvic floor and of the big toe flexor to level S3 and that of the anal sphincter and of the perineum to level S4. The cystomanometric response is generally obtained by stimulation of S3, but sometimes of S4 and more rarely of S2. The S2 is sectioned along a length of 3 to 4 cm (or crushed). The motor roots are carefully freed from their arachnoid bridges and arranged in their respective stimulation compartment. Normally, the upper median compartment receives S3 while S2 is installed in the side compartments and S4 and S5 occupy the lower compartment. The dura mater should be air-tightly re-closed. The leads feeding the traps to roots run along a silicone mantle that ensures such airtightness. The second thoracic stage can be carried out in the same ventral decubitus position (some prefer the lateral decubitus [2] or even dorsal decubitus [10]). The cutaneous incision is performed in accordance with the rib-cage. A small pocket is made for the radio-receiver which is fixed to the thoracic wall (Fig. 4). Connection of the three leads corresponding to the three pairs of roots is performed by subcutaneous tunnelling, after clinical and

cystomanometric checking of the function of the device (Fig. 5). Total surgical time varies from 4 to 6 hours.

#### *Extradural approach*

The extradural method has been developed under the name of «Barcelona technique» [17]. Rhizotomy is performed first. After a dorsolumbar laminectomy, the sensory roots are sectioned where they emerge from the spinal cord. Opening the sacral canal allows placing the stimulation electrodes, extradurally, around each of the roots. The leads are connected to the subcutaneous radio-receiver. The extradural method does not require dissection of the roots in the intradural casing. These can be kept intact [22] in cases of contra-indication of the intradural method (infection, fibrosis, or presence of osteosynthesis material). This allows to have other options in the event of failure of the original approach.

#### *Sacral approach*

This technique, described recently by Robert *et al.* [13] may be called the “Nantes technique”. It allows implantation in one procedure, and with only one posterior access. It combines the intradural method (rhizotomy and closure of the dural sac) and the extradural method (placement of the electrodes at the sacral root level). It also allows a shorter procedure time by carrying out rhizotomies, with precision, under the control of radicular stimulation, similarly to the intradural approach. Additionally, this approach limits the risk of root damage.

### **Results**

Ninety percent (90%) of the patients describe that their quality of life improves significantly [10]. No series have reported deaths due to the technique [19]. The results for urinary reflex incontinence are consistent in the teams practicing complete rhizotomies; nearly 90% of the patients became continent [11]. This result is associated with a significant improvement in bladder compliance which may even return to normal. This is directly related to the precision and the number of rhizotomies performed. Thus, in the majority of patients, continence is definitively regained. The majority of patients void their bladder completely with a residual volume of less than 50 ml. These figures show the effectiveness of the stimulation device. This effectiveness remains stable in the long-term [24]. Of the patients, 80–100% had recurrent urinary infections preoperatively, sometimes life threatening. After implantation, 70% of the patients have sterile urine,

the others have nonfeverish transient leucobacteriuria which does not require specific treatment. The morbidity and mortality of infectious origin are greatly reduced among implanted patients. It is frequently noted that the vesico-ureteral reflux disappears, and urinary lithiases are reduced [22]. Renal function is constantly protected, provided that the stimulation parameters are correctly programmed. The Brindley technique does not cause deterioration of either the upper urinary tract or its function [20]. Autonomous hyperreflexia (AHR) is present among patients whose lesion is above the level of the sympathetic centers, and is associated with reflex release of catecholamines. Most series report reduction, or even disappearance of AHR. New cases of AHR have never been noted after surgery. These positive effects are due to the rhizotomies [22].

The erection stimulation program functions through stimulation of the S2 roots. Even if it is effective in 2/3 of the cases, in reality, it is only used by 1 patient out of 3 [6]. S4 root stimulation gives an improvement in the function of defecation by improving fecal transport into the rectum. Initially, the defecation stimulation program is regularly used by patients; however, usage later becomes occasional [6]. In addition, stimulation of S3 for micturitional use is sufficient to control the fecal function.

The spasticity of the lower limbs can be increased in the immediate postoperative period but this is always transient. It seems that, the hypertonia attacks become less severe. A reduction in the spasticity of the urethral striated sphincter is also observed. Sensory rhizotomy of L5 and S1 may be carried out during the implant procedure in patients presenting preoperatively with severe spasticity of the lower limbs, [10]. The Brindley system is not a contra-indication to the implantation of a Baclofen pump [22].

### Impact on the quality of life

The Qualiveen scale [8] measures the specific impact of urinary problems on the quality of life of the spinal cord injured patient (IPSU) and explores 4 fields: embarrassment, constraints, fears in daily life, and a general index of the quality of life (QOL). This scale was validated on a reference population of 400 spinal cord-injured patients and thus serves to give reference scores. A recent study on the evaluation of the QOL using the Qualiveen scale has been undertaken among 37 patients subjected to the Brindley technique. In this study, the average score of IPSU was 0.84 in the Brindley technique group and 1.49 in the reference population, suggest-

ing that the specific impact of urinary disorders on the QOL is smaller in the implanted population; in the same way, the median of the general index of QOL was 0.89 compared to 0.23 in the reference population, also suggesting a better QOL among implanted patients [23].

### Economic consequences

Studies on the financial consequences of the Brindley technique showed a reduction in the annual costs per patient ranging from 3,000 to 8,000 dollars in the Netherlands [25] and from 8,000 to 14,000 dollars in the United States [9]. In the medium- to long-term, the Brindley technique is less expensive (after 8 and 5 years in the Netherlands and USA, respectively). However, the high variability of data and the differences in social security systems between countries show that this type of study must be carried out in each country concerned. The French ministry of health initiated a research program with the aim to measure the medico-economic impact of the Brindley technique on both its social security system and patient health. The results will be known in a few years.

### Complications related to the technique

The CSF leakage risk is 2–3% [10]. One can observe a subcutaneous collection, sometimes up to the radio-receiver, but repeat surgery is rarely required. Maintenance of the decubitus position, prescription of Acetazolamide or of Glycerotone and delayed bladder stimulation (from one to several weeks) allow these effusions to disappear. Infection is a serious complication because it may require removal of the system and restoration of intermittent catheterizations. Its rate can reach 2.6% [24]. Meningitis is very rare. Contamination is caused sometimes through contiguity, mainly during surgery or hematogenically, manifesting itself several months after placing the implant. This risk should be evaluated as a potential indication for perioperative antibiotic prophylactic therapy. It is surprising that out of hundreds of implantations, no destabilisation of the spine was ever reported after placing a stimulator in patients with a deficient muscular structure. Only a pathological fracture in a patient with suspected osteomyelitis [9] and a non-significant aggravation of a pre-existent lumbar scoliosis were reported [21].

Lesions of anterior roots arise in 0–4% of cases [24]; they manifest themselves by the impossibility of obtaining effective bladder pressures through stimulation.

Intraoperative stimulation does not allow the prediction of these results that only appear later, between the 4th and the 7th post-operative day [21]. It is most often a neurapraxia that recovers within a period of 2–12 months. The intradural method theoretically exposes the patients to greater lesional risks [5].

Rhizotomies should involve all afferents from the bladder, i.e. bilaterally the posterior roots S2–S4, and for certain S5. They improve continence and protect the upper urinary tract by favouring low pressure refilling. Incomplete rhizotomies are commonly the result of a technical fault [1]. However, anatomical variations may exist [18] and contribute to the technique's inefficiency (variation of the number of levels regarding the bladder, localisation of the bladder afferents conveyed by the anterior roots, reflex activities contained in the underlying tracts). For eliminating a pronounced hyperactivity, anticholinergics can be used [9] but more often, it is necessary to perform additional rhizotomies. More rarely, the suggestion will be to divide or block either chemically or electrically the pudendal nerve. This nerve which innervates the striated sphincter, contains afferent fibers involved in segmentary reflexes. In men, rhizotomies lead to a complete loss of reflex erections and ejaculations which have great psychological importance. It is sometimes possible not to section the S2 posterior roots at the cost of a persistent hyperreflexia. The use of four or eight track implants allowing isolation of the intact posterior roots is possible during the time of stimulation of the motor roots [10]. The time needed for a failure to appear can vary from 1 month to 9 years [6]. About 7% of patients need repeat surgery [14], more often because of lead breaks, or faults in the receiver. The traps to the roots have never been questioned [1]. These deficiencies manifest themselves through intermittent dysfunctioning of the device. X-rays only rarely show a break of one of the leads, but the device can be replaced and the leads reconnected.

## Conclusion

The Brindley technique is indicated in all para- or tetraplegic patients, presenting with a “supra-sacral bladder” resistant to the usual techniques of therapeutic re-education for incontinence, or in patients in whom the upper urinary tract is at risk because of the complications of neuropathic bladder. A multi-disciplinary medical team is required to implement the Brindley technique. The Brindley technique should be considered prior to any interventional urological procedure which aims to

modify the anatomy of the lower urinary tract. In functional terms, the results are such that the future indications for Brindley technique should be expanded. Indeed, the technique involves the functional restoration of previously uncontrolled micturition, by electrically-induced controlled neural stimulation. Within this framework, the Brindley system can be proposed as an alternative not only to intermittent catheterizations, but also for the treatment of reflex micturition.

## References

1. Barat M, Egon G, Daverat P, Colombel P, Guérin J (1993) Why does continence fail after sacral anterior root stimulator? *Neurourol Urodyn* 12: 507–508
2. Bauchet L, Segnarbieux F, Martinazzo G, Frerebeau P, Ohanna F (2001) Traitement neurochirurgical de la vessie hyperactive chez le blessé médullaire. *Neurochirurgie* 47: 13–24
3. Blok BF, Holstege G (1994) Direct projections from the periaqueductal gray to the pontine micturition center (M-region). An anterograde and retrograde tracing study in the cat. *Neurosci Lett* 166: 93–96
4. Bradley WE, Conway CJ (1966) Bladder representation in the pontine mesencephalic reticular formation. *Exp Neurol* 16: 237–249
5. Brindley GS (1994) The first 50 patients with sacral root stimulator implants: general description. *Paraplegia* 32: 795–805
6. Brindley GS (1995) The first 500 sacral anterior root stimulators: implant failures and their repair. *Paraplegia* 33: 5–9
7. Burchiel KJ, Hsu FPK (2001) Pain and spasticity after spinal cord injury. *Spine* 26: 146–160
8. Costa P, Perrouin-Verbe B, Colvez A, Didier JP, Marquis P, Marrel A, Amarenco G, Espirac B, Leriche A (2001) Quality of Life in spinal cord injury patients with urinary difficulties: development and validation of Qualiveen. *Eur Urol* 39: 107–113
9. Creasey GH, Dahlberg JE (2001) Economic consequences of an implanted neuroprosthesis for bladder and bowel management. *Arch Phys Med Rehab* 82: 1520–1525
10. Egon G, Barat M, Colombel P, Visentin C, Isambert JL, Guérin J (1998) Implantation of anterior sacral root stimulators combined with posterior sacral rhizotomy in spinal injury patients. *World J Urol* 16: 342–349
11. Egon G, Colombel P, Isambert JL, Guérin J, Barat M (1993) Evolution of bladder contraction in course of time after implantation of a sacral anterior root stimulator. *Neurourol Urodyn* 12: 509–512
12. Guérin J, Bioulac B (1979) The anatomical and physiological organization of motor activity in the spinal cord. *Anatomia Clinica* 1: 267–289
13. Hamel O, Perrouin-Verbe B, Robert R (2004) Brindley technique with intradural deafferentation and extradural implantation by a single sacral laminectomy. *Neurochirurgie* 50(6): 661–666
14. Kutzemberger J, Domurath B, Sauerwein D (2005) Spastic bladder and spinal cord injury: seventeen years of experience with sacral deafferentation and implantation of an anterior root stimulator. *Artif Organs* 29(3): 239–241
15. Mc Donagh RP, Forster DMC, Thomas DG (1990) Urinary continence in spinal injury patients following complete sacral posterior rhizotomy. *Br J Urol* 66: 618–922
16. National spinal cord injury association (NSCIA) <http://www.spinalcord.org/>
17. Sarrias M, Sarrias F, Borau A (1993) The «barcelona» technique. *Neurourol Urodyn* 12: 495–496



18. Schurch B, Rodic B, Jeanmonod D (1997) Posterior sacral rhizotomy and intradural anterior sacral root stimulation for treatment of the spastic bladder in spinal cord injured patients. *J Urol* 157: 610–614
19. Seif C, Junemann KP, Braun PM (2004) Deafferentation of the urinary bladder and implantation of a sacral anterior root stimulator (SARS) for treatment of the neurogenic bladder in paraplegic patients. *Biomed Tech (Berl)* 49(4): 88–92
20. Van der Aa HE, Hermens H, Alleman E, Vorsteveld H (1995) Sacral anterior root stimulation for bladder control in patients with complete lesion of the spinal cord. *Acta Neurochir (Wien)* 134: 88–89
21. Van Kerrebroeck PEV, Koldewijn E, Wijkstra H, Debruyne FMJ (1991) Intradural sacral rhizotomies and implantation of an anterior sacral root stimulator in the treatment of neurogenic bladder dysfunction after spinal cord injury. *World J Urol* 9: 126–132
22. Van Kerrebroeck PEV, Van der Aa HE, Bosch JLHR, Koldewijn EL, Vorsteveld JHC, Debruyne FMJ (1997) Sacral rhizotomies and electrical bladder stimulation in spinal cord injury. *Eur Urol* 31: 263–271
23. Vastenholt JM, Snoek GJ, Buschman HPJ, Van der Aa HE, Alleman ERJ, Ijzerman MJ (2003) A 7-year follow-up of sacral anterior root stimulation for bladder control in patients with a spinal cord injury: quality of life and user' experiences. *Spinal Cord* 4: 397–402
24. Vignes JR, Liguoro D, Sesay M, Barat M, Guérin J (2001) Dorsal rhizotomy with anterior sacral root stimulation for neurogenic bladder. *Stereotact Funct Neurosurg* 76: 243–245
25. Wielink G, Essink-Bot ML, Van Kerrebroeck PE, Rutten FF (1997) Sacral rhizotomies and electrical bladder stimulation in spinal cord injury. 2. Cost-effectiveness and quality of life analysis. Dutch Study Group on sacral anterior root stimulation. *Eur Urol* 31: 441–446

Correspondence: Luc Bauchet, Department of Neurosurgery CHU de Montpellier, Hôpital Gui de Chauliac, 80 avenue Augustin Fliche, 34 295 Montpellier cedex, France. e-mail: l-bauchet@chu-montpellier.fr