

pose a modified equation, whereby dropping the constant 20 and taking the reciprocal yields,

$$\text{Snellen Acuity} = 10^{-[(55 - X)/50]}, \quad (1)$$

where X is the number of letters read correctly from the chart. This yields Snellen acuity directly in its decimal form, which may be more useful for certain statistical analyses.

Equation 1 is approximately, but not exactly, equivalent to the related equation,

$$\text{Snellen Acuity} = 2^{-[(55 - X)/15]}, \quad (2)$$

which can be substituted with minimal error. This alternative formula relates the base 2 to the exponential denominator 15, also echoing the chart design wherein the visual angle doubles every 15 letters (3 lines). Equation 2 likewise yields Snellen acuity in decimal form.

When using equation 1, for example, if all Bailey-Lovie letters (X = 70) are correctly identified, the Snellen acuity =  $10^{-(-0.3)} = 2.00 = 20/10$ . For X = 55, Snellen acuity =  $10^0 = 1 = 20/20$ ; X = 58,  $1.15 = 20/17$ ; and X = 40,  $0.50 = 20/40$ . By way of comparison, if equation 2 is used substituting X = 40, then Snellen acuity =  $2^{-1} = 1/2 = 20/40$ , affirming the interchangeability (within tolerances) of the two equations.

Equations 1 and 2 are, indeed, merely special cases of a general expression. There exists a family of exponential equations, described by the expression,

$$\text{Snellen Acuity} = a^{-[(55 - X)/50 \log_{10} a]}, \quad (3)$$

where a is any positive real number, except 1. For example, substituting  $a = 100$  and X = 70 yields the Snellen acuity =  $100^{-(-0.15)} = 2.00 = 20/10$ . However, for ease of calculation, equation 1 remains the most convenient.

JEFFREY W. KALENAK, MD  
Cleveland, Ohio

1. Holladay JT, Prager TC. Snellen equivalent for the Bailey-Lovie acuity chart. *Arch Ophthalmol*. 1989;107:955.

2. Bailey IL, Lovie JE. New design principles for visual acuity letter charts. *Am J Optom Physiol Opt*. 1976;53:740-745.

### Magnetic Resonance Imaging and Retinal Tacks

*To the Editor.*—As magnetic resonance imaging (MRI) has become an increasingly useful and necessary adjunct to patient care, the potential problem of scanning patients with intraocular metal has been noted.<sup>1</sup> The possible presence of minute quantities of ferromagnetic materials in retinal tacks, in view of the strength of the magnetic field produced, has led to concern. A general policy has been to exclude patients with retinal tacks from MRI scanning.

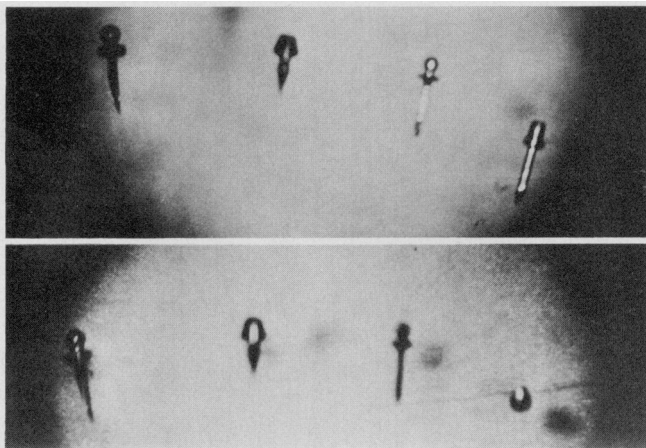
One previous report, testing two types of retinal tacks, suggests that MRI may be safe.<sup>2</sup> We know of at least seven varieties of tacks available at the Bascom Palmer Eye Institute, Miami, Fla, and have included them in a study exposing them to two magnetic sources: an electromagnet of approximately 0.1 T (Mueller Giant Eye Magnet, 115 V, 60 Hz, alternating current, V. Mueller and Co, Chicago, Ill), and a 1.5-T MRI system (Picker Vista, Cleveland, Ohio).

All seven tacks were initially suspended horizontally in the middle of hardened commercial Knox gelatin (Knox Gelatin Inc, Englewood Cliffs, NJ) in standard Petri dishes. The Petri dishes were placed next to the electromagnet with a contact distance of 4.5 cm for a duration of 1 minute. The Petri dishes were then placed within the MRI scanner for 30 minutes. The position of the tacks was documented with color photography, both before and after each magnetic exposure.

Six types of tacks were then inserted into the peripheral

retinas of one eye of a New Zealand white rabbit. Each rabbit was placed under xylazine hydrochloride/ketamine hydrochloride 1:1 anesthesia and a pars plana vitrectomy and lensectomy were performed prior to insertion of the tacks. The tacks were then viewed weekly. Spontaneous dislocation or intrusion of several tacks required repositioning. The rabbits were then exposed to MRI with the 1.5-T system for 30 minutes while under anesthesia. The mean time between tack insertion and scanning was 32 days, ranging from 1 to 98 days. The position of all tacks was documented with color photography and indirect ophthalmoscopy directly before and after scanning. The animals were euthanized after imaging with an intravenous dose of T-61 (Taylor Pharmaceutical Co, Decatur, Ill). All animals were housed and treated in accord with the Association for Research in Vision and Ophthalmology's Resolution on the Care of Experimental Animals.

Of the tacks placed within gelatin, only one showed movement. This was the Western European tack, which showed a 90° change of orientation when placed in front of the electromagnet (Figure). It again showed movement when MRI was performed. In the rabbit model, only the Western European tack moved when exposed to maximum magnetic energy. This tack was partially dislodged from the retina prior to scanning. However, after scanning it was found to be completely dislodged from the retina, with a new orientation. No retinal tear was created by this movement (Table).



Top, Tacks suspended in gelatin in Petri dish prior to exposure to the magnetic field. Left to right, Bascom Palmer Eye Institute tack, Coopervision tack, Duke tack, and Western European tack. Bottom, Tacks suspended in gelatin in Petri dish immediately after application of magnetic field from Mueller Giant Eye Magnet (V. Mueller and Co, Chicago, Ill). Note that the Western European tack on the far right has reoriented itself by 90°.

Composition and Movement of Retinal Tacks in Animal Model With Magnetic Resonance Imaging Scanning		
Type of Tack	Composition	Movement
Norton staple	90% platinum / 10% rhodium	No
Ruby	Aluminum tetraoxide	No
Western European	Martensitic stainless steel	Yes
Coopervision	Titanium alloy	No (2 tacks)
Duke	No. 303 austenitic stainless steel	No
Bascom Palmer Eye Institute	No. 303 austenitic stainless steel	No (2 tacks)

The majority of retinal tacks now made are produced from materials known to have little or no magnetic attraction. Still, in light of this knowledge, the radiologic community has been uneasy about scanning such patients with MRI. The report by Kelly et al<sup>1</sup> of an occult intraocular iron foreign body that resulted in vitreous hemorrhage underlines the potential for severe damage that can result from MRI scans. Other studies have shown that scanning of non-ferromagnetic materials within the eye is safe. Roberts et al<sup>3</sup> scanned platinum and titanium metallic loops from old-style intraocular lenses, showing that these do not move in MRI scanners.

We can assume that the Western European tack we tested contained a ferromagnetic material that accounted for its movement in both the commercial gelatin preparation and the rabbit model. We believe that this tack is manufactured of a martensitic stainless steel, heat-hardenable metal, usually selected for the fabrication of surgical blades. When exposed to a magnetic field in the Mueller magnet and MRI unit, the position of this tack was affected. However, no intraocular damage occurred due to this movement. While tack movement might well result in retinal detachment or hole formation, it does not appear that the force generated on a tack is enough to cause damage to the orbit or brain. All the other tacks that we studied did not move within the eye when subjected to the magnetic fields.

Therefore, it appears that MRI scanning is safe in the

majority of patients who have retinal tacks. Certainly, if patients or their primary physicians had knowledge of the type of tack that was inserted, a rational decision could be made as to the appropriateness of an MRI scan when it appears indicated.

DEANNA W. ALBERT, MD  
KARL R. OLSON, MD  
JEAN-MARIE PAREL, ING ETS-G  
ELEUT HERNANDEZ  
WILLIAM LEE  
ROBERT QUENCER, MD  
Miami, Fla

This investigation was supported in part by grants from the Florida High Technology and Industrial Council, Tallahassee, Fla; the Helena Rubinstein Foundation, New York, NY; the Veterans Administration Medical Center, Miami, Fla; and by an unrestricted departmental grant from Research to Prevent Blindness Inc, New York, NY.

This report was presented in part at the Bascom Palmer Eye Institute Residents' Days, Miami, Fla, June 10, 1988.

1. Kelly WM, Paglen PG, Pearson JA, San Diego AG, Soloman MA. Ferromagnetism of intraocular foreign body causes unilateral blindness after MR study. *AJNR*. 1986;7:243-245.
2. Joondeph BC, Peyman GA, Mafee MF, Joondeph HC. Magnetic resonance imaging and retinal tacks. *Arch Ophthalmol*. 1987;105:1479-1480.
3. Roberts CW, Haik BG, Cahill P. Magnetic resonance imaging of metal loop intraocular lenses. *Am J Ophthalmol*. 1987;104:427.

### Currently in Other AMA Journals

#### ARCHIVES OF DERMATOLOGY

##### Physical Properties of Aerosols Produced by Dermabrasion

J. Michael Wentzell, MD; June K. Robinson, MD; Joseph M. Wentzell, Jr; David E. Schwartz, PhD; Steven E. Carlson (*Arch Dermatol*. 1989;125:1637-1643)

##### Positive Fluorescent Treponemal Antibody Absorption Test in Cerebrospinal Fluid of Nonsyphilitic Persons Infected With Human Immunodeficiency Virus

Winfried Breustedt, MD; Rosemaire Bitta; Niels Sonnichsen, MD (*Arch Dermatol*. 1989;125:1712-1717)

#### ARCHIVES OF NEUROLOGY

##### Glucose Uptake by Gliomas After Treatment: A Positron Emission Tomographic Study

Jack M. Rozental, MD, PhD; Ross L. Levine, MD; Robert J. Nickles, PhD; Jeffrey A. Dobkin, MD (*Arch Neurol*. 1989;46:1302-1307)

##### Abnormal Ocular Pneumoplethysmographic Results in Unilateral Neovascular Glaucoma

Eric P. Shakin, MD; Thomas M. Bosley, MD; William Gee, MD; James Reed III, PhD; Gary C. Brown, MD; Robert C. Sergott, MD; Peter J. Savino (*Arch Neurol*. 1989;46:1308-1310)

##### Vertical One-and-a-Half Syndrome: Supranuclear Downgaze Paralysis With Monocular Elevation Palsy

Dirk Deleu, MD; Therese Buisseret, MD; Guy Ebinger, MD (*Arch Neurol*. 1989;46:1361-1363)