

Artifact reduction with a wideband late gadolinium enhancement (LGE) MRI technique for patients with implanted cardiac devices: a two-center study

Shams Rashid^{1*}, Adam Plotnik¹, Harold Litt², Yuchi Han^{3,4}, Stanislas Rapacchi¹, Roderick H Tung⁵, Kalyanam Shivkumar⁵, J Paul Finn^{1,6}, Peng Hu^{1,6}

From 17th Annual SCMR Scientific Sessions
New Orleans, LA, USA. 16-19 January 2014

Background

Late gadolinium enhancement (LGE) cardiac MRI is the clinical gold standard for non-invasive characterization of myocardial scar [1]. However, up to 75% of patients who may benefit from LGE MRI have preexisting implanted cardiac devices such as implantable cardioverter defibrillators (ICD) and pacemakers (PM) [2]. The presence of an ICD produces hyper-intensity (HI) image artifacts in LGE (Figure 1) and can prevent assessment of myocardial scar. We recently proposed a wideband LGE MRI technique that removes these artifacts in ICD patients [3,4]. In this abstract, we present our two-center experience of using this wideband LGE sequence on a cohort of patients with ICDs who were referred to cardiac MRI.

Methods

The HI artifacts in LGE images of ICD patients are caused by severe off-resonance produced by the ICD. Spins in the affected myocardium are not inverted by the IR pulse and give rise to the HI artifacts. In the new sequence, a wideband (3.8 kHz) IR pulse was implemented to replace the standard pulse with 1.1 kHz spectral bandwidth, thereby eliminating the HI artifacts [3,4]. The wideband LGE was implemented at the medical centers of the University of California, Los Angeles (UCLA), and the University of Pennsylvania (Penn). A total of 25 patients with ICDs and PMs (UCLA: 19, Penn: 6),

were imaged using the conventional and the wideband LGE technique. In each image set, the left ventricle was divided into 13 segments (basal, mid-ventricular, and apical, each having posterior, lateral, anterior and septal segments, and an individual apex segment). Artifact-containing segments in each patient were identified by two attending radiologists.

Results

No HI artifacts were present in the conventional LGE images of the 3 PM patients included in the study, as well as 2 ICD patients owing to large distance of the ICD from the heart. In the remaining 20 ICD patients, HI artifacts were present in 5.6 ± 2.4 segments per patient in the conventional LGE images. All artifacts were completely eliminated in the wideband LGE images. Figure 1 shows examples of LGE images from the conventional and wideband LGE technique. Figure 2 shows the number of patients that had HI artifacts in each of the 13 segments. The three segments with the largest number of artifacts are the apex, the apical lateral and the mid-ventricular anterior segment.

Conclusions

We have developed a wideband LGE technique to eliminate the HI artifacts seen in LGE MRI of patients with ICDs. This technique was implemented at two centers and successfully evaluated on 25 patients, leading

¹Department of Radiological Sciences, University of California, Los Angeles, Los Angeles, California, USA

Full list of author information is available at the end of the article

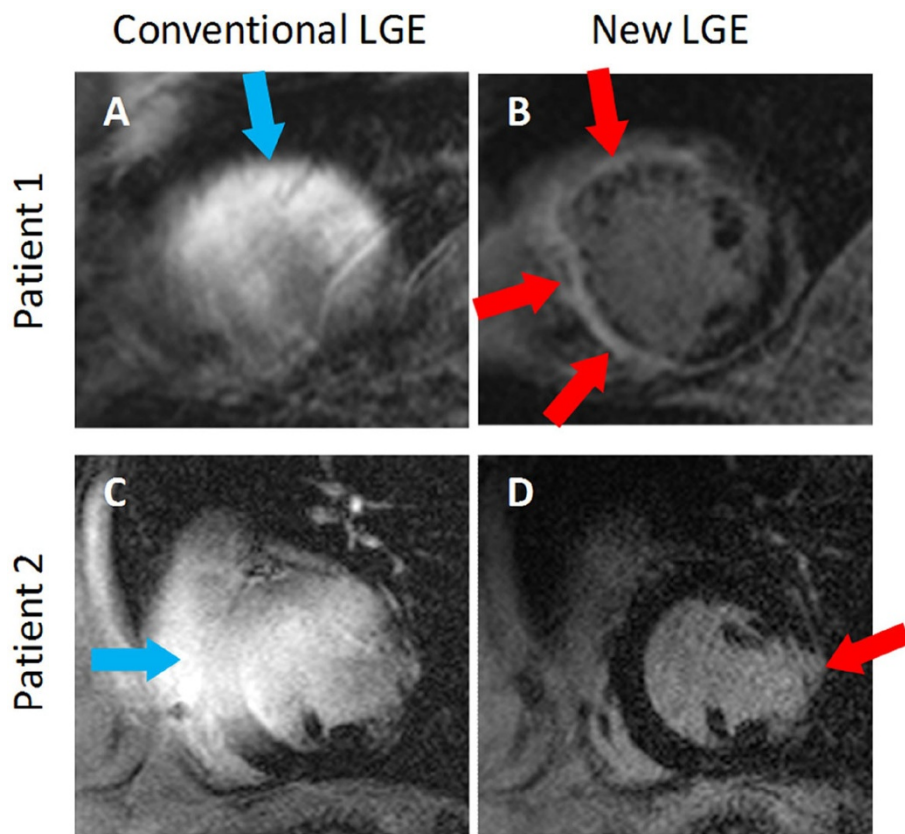


Figure 1 Examples of conventional LGE (A & C) and wideband LGE (B & D) images from two patients. In both patients, severe hyperintensity artifacts (blue arrows) are produced in the conventional sequence, which prevents assessment of scar. The artifacts are completely eliminated by the wideband LGE technique. Scar tissue (red arrows) was identified in the anterior and septal walls of the left ventricle in Patient 1, and in the lateral wall of the left ventricle in Patient 2.

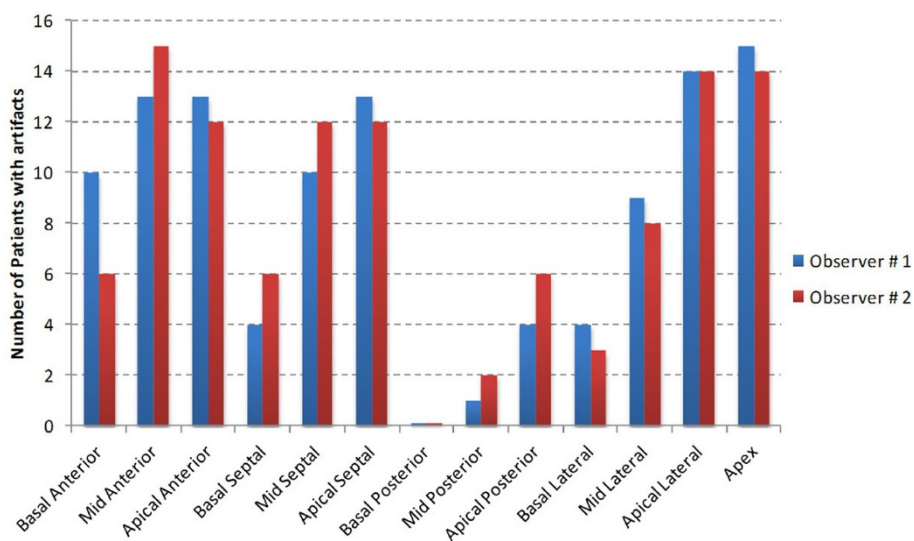


Figure 2 Graph showing the number of patients who presented artifacts in each of the 13 segments of the left ventricle in the conventional LGE images. The 3 segments that had the highest occurrence of artifacts are the apex, the apical lateral segment and the mid-ventricular anterior segment.

to prominent reduction of the HI artifacts. The wideband LGE technique may enable widespread utility of LGE MRI in patients with implanted cardiac devices, in whom LGE MRI otherwise could not be used for diagnosis.

Funding

NIH 1R21 HL118533

Authors' details

¹Department of Radiological Sciences, University of California, Los Angeles, Los Angeles, California, USA. ²Department of Radiology, University of Pennsylvania Perelman School of Medicine, Philadelphia, Pennsylvania, USA. ³Department of Medicine, University of Pennsylvania Perelman School of Medicine, Philadelphia, Pennsylvania, USA. ⁴Penn Cardiovascular Institute, University of Pennsylvania Perelman School of Medicine, Philadelphia, Pennsylvania, USA. ⁵UCLA Cardiac Arrhythmia Center, UCLA Health System, Los Angeles, California, USA. ⁶Biomedical Physics Inter-Departmental Graduate Program, University of California, Los Angeles, Los Angeles, California, USA.

Published: 16 January 2014

References

1. Dickfield T, et al: *Circ Arrhythm Electrophysiol* 2011, **4**(2):172.
2. Kalin R, et al: *Pacing Clin Electrophysiol* 2005, **28**(4):326.
3. Rashid S, et al: *Radiology*.
4. Rashid S, et al: *ISMRM Proceedings* 2013, #3407.

doi:10.1186/1532-429X-16-S1-O29

Cite this article as: Rashid et al.: Artifact reduction with a wideband late gadolinium enhancement (LGE) MRI technique for patients with implanted cardiac devices: a two-center study. *Journal of Cardiovascular Magnetic Resonance* 2014 **16**(Suppl 1):O29.

Submit your next manuscript to BioMed Central
and take full advantage of:

- Convenient online submission
- Thorough peer review
- No space constraints or color figure charges
- Immediate publication on acceptance
- Inclusion in PubMed, CAS, Scopus and Google Scholar
- Research which is freely available for redistribution

Submit your manuscript at
www.biomedcentral.com/submit

