

# 3T MR Imaging of Cartilage using 3D Dual Echo Steady State (DESS)

Rashmi S. Thakkar, M.D.<sup>1</sup>; Aaron J Flammang, MBA-BSRT (R) (MR)<sup>2</sup>; Avneesh Chhabra, M.D.<sup>1</sup>; Abraham Padua, RT (R)<sup>3</sup>; John A. Carrino, M.D., M.P.H.<sup>1</sup>

<sup>1</sup>Johns Hopkins University School of Medicine, Russell H. Morgan Department of Radiology and Radiological Science, Baltimore, MD, USA

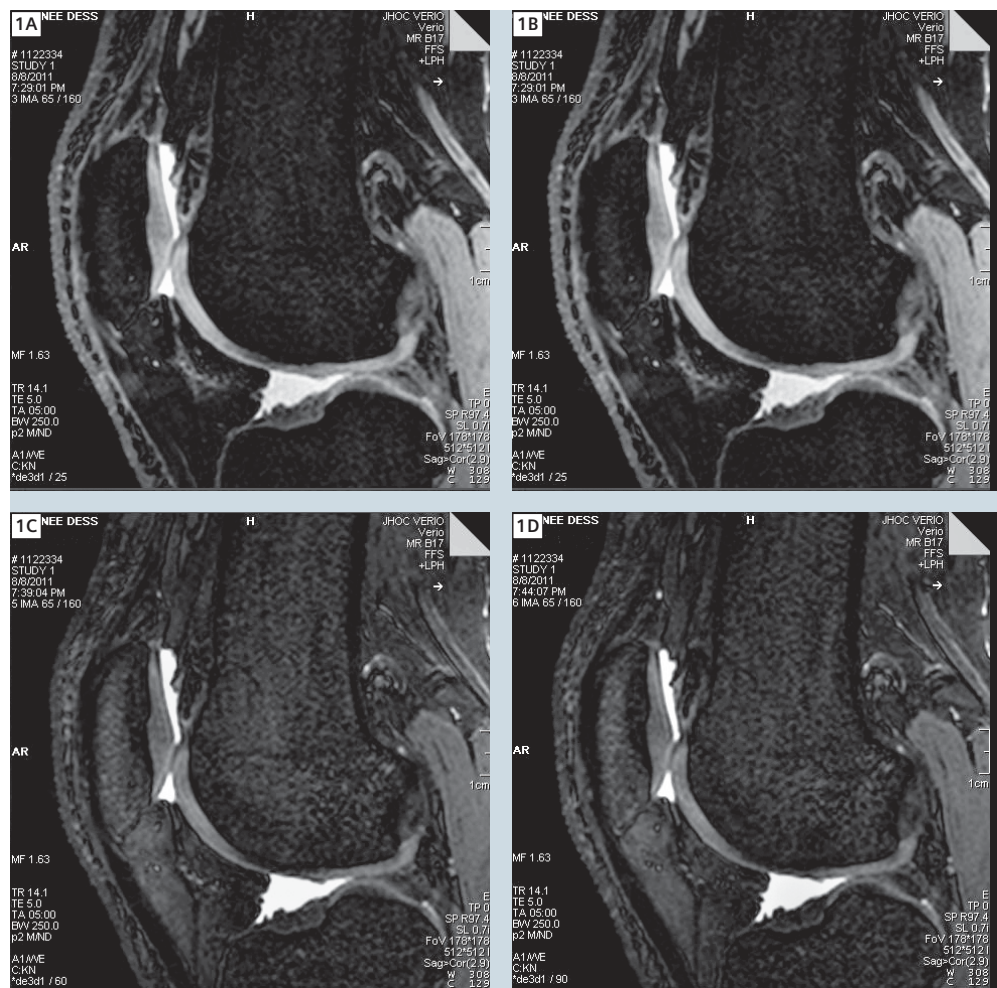
<sup>2</sup>Siemens Corporate Research (CAMI), Baltimore, MD, USA

<sup>3</sup>Siemens Healthcare, Malvern, PA, USA

## Introduction

Magnetic resonance imaging (MRI), with its excellent soft tissue contrast is currently the best imaging technique available for the assessment of articular cartilage [1]. In the detection of cartilage defects, three-dimensional (3D) MRI is particularly useful because cartilage is a thin sheet wrapped around complex anatomical structure. Isotropic, high resolution voxels enable reformatting of images into more convenient planes for viewing.

An MRI technique specifically for imaging cartilage should be able to accurately assess cartilage thickness and volume, depict morphological changes and show subtleties within the cartilage while minimizing artifactual signal alterations. In addition, it is necessary to evaluate subchondral bone for abnormalities. 3T MR scanners with multi-channel dedicated coils allow to obtain image data with high resolution as well as sufficient signal-to-noise ratio (SNR) and contrast-to-noise ratio (CNR) [2]. Conventional spin echo and turbo spin echo sequences (T1, T2, and PD with or without fat suppression) as well as gradient echo techniques (incoherent GRE sequence, such as FLASH and coherent or steady state sequence, such as DESS) have been used for many years in cartilage imaging. Spin echo based approaches have clearly dominated due mostly to efficiency with respect to scan time.



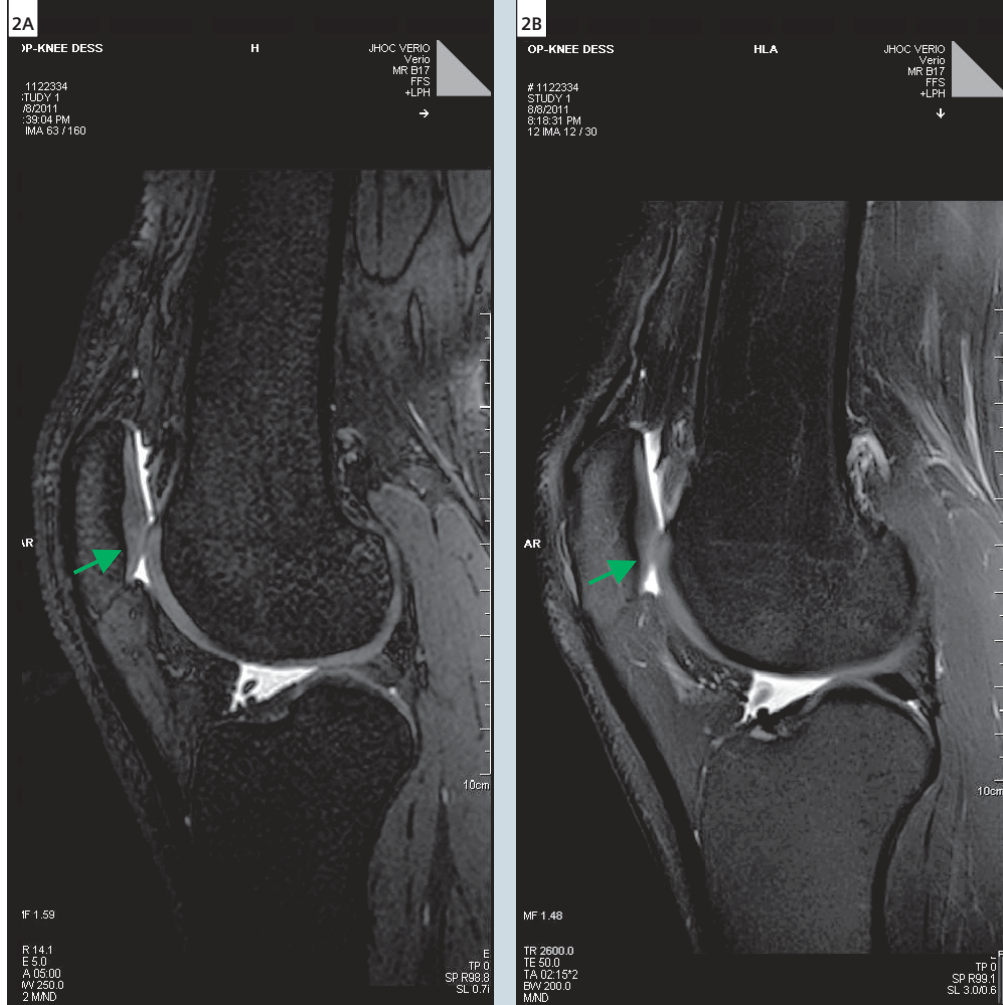
**1** Sagittal water selective 3D DESS imaging of the knee (TR/TE 14.1/5 ms) at various flip angles (1A = 25°, 1B = 45°, 1C = 60°, 1D = 90°). With the flip angle of 60° there is highest signal intensity of synovial fluid with highest contrast-to-noise ratio of the cartilage.

In this article, we would like to describe the use of Dual Echo Steady State (DESS) in imaging of the articular cartilage on the Siemens MAGNETOM Verio.

**DESS**

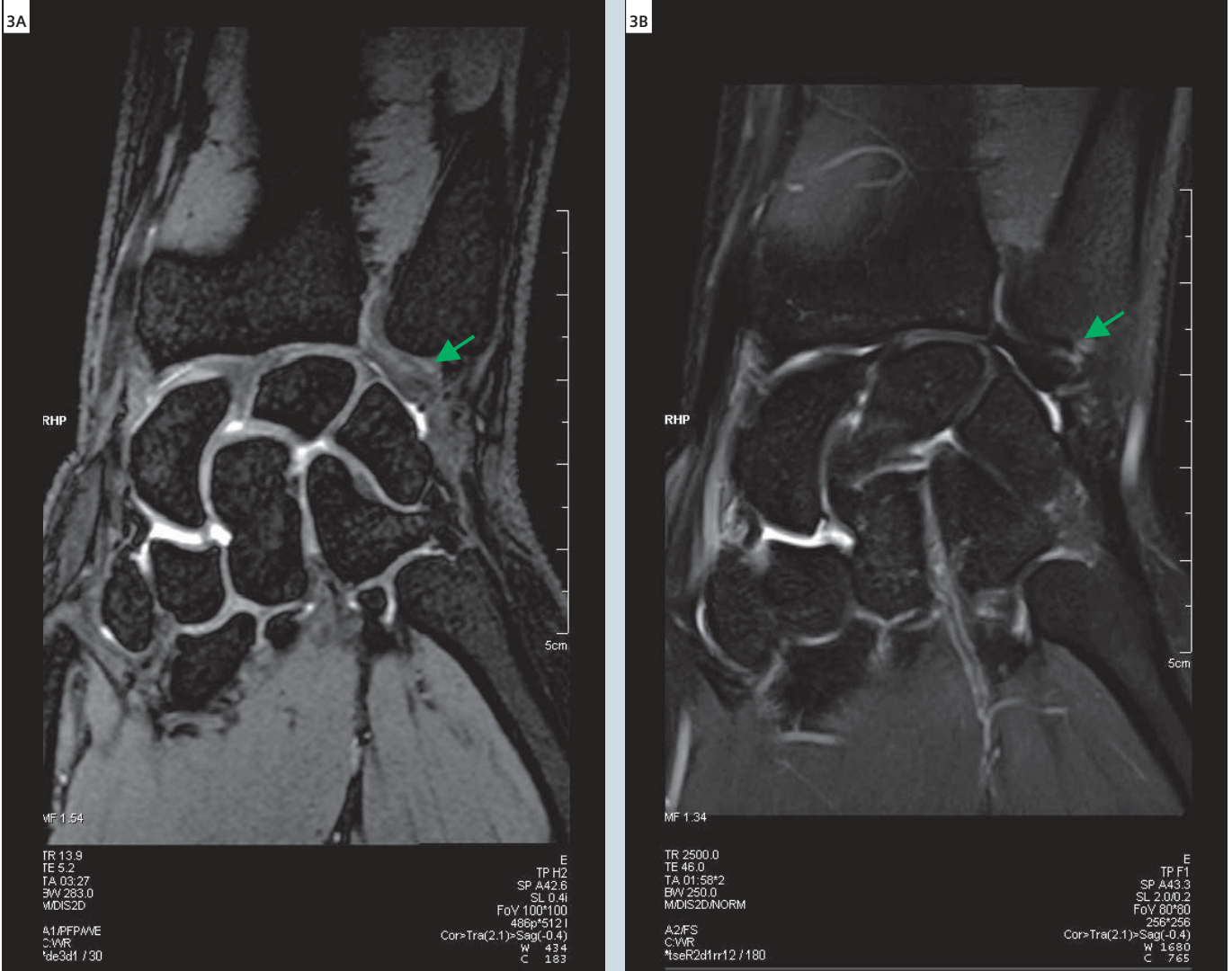
Dual Echo Steady State (DESS) is a 3D coherent (steady state) GRE sequence. Steady state sequences (FISP, TrueFISP, DESS, PSIF, CISS) have two major characteristics. First, TR is too short for transverse magnetization to decay before the next RF pulse is applied. Second, slice selective (or slab selective) RF pulses are evenly spaced. When phase-coherent RF pulses of the same flip angle are applied with a constant TR that is shorter than the T2 of the tissue, a dynamic equilibrium is achieved between transverse magnetization (TM) and longitudinal magnetization (LM) [3]. Once this equilibrium is reached, two types of signals are produced. The first type is post excitation signal (S+) that consists of free induction decay (FID) arising from the most recent RF pulse. The second signal is an echo reformation that occurs prior to excitation (S-) and results when residual echo is refocused at the time of the subsequent RF pulse [4].

Based on the theory of Bruder et al. [5], the simultaneous acquisition of two separate, steady state, free precession (SSFP) echoes allows the formation of two MR images with clearly different contrasts: S+ = FISP (fast imaging steady precession); and S- = PSIF (reversed FISP). DESS combines these signals into one by applying a sum of squares calculation to both echoes. The PSIF part of the sequence leads to a high T2 contrast, whereas the FISP part provides representative morphological images with a contrast dominated by the T1/T2 ratio. In principle, the different T2 weightings of both echoes (and images), allows the calculation of quantitative T2 maps with a certain functional dependence on T1 based on the chosen flip angle. Hence, the DESS sequence has the potential advantage to combine morphological and functional analysis from the same data set with high



**2** Sagittal MRI image of the knee. **(2A)** 3D DESS (TR/TE 14.1/5 ms) at flip angle 60°. **(2B)** 2D proton density with fat saturation (TR/TE 2600/50 ms). PD fat sat **(2B)** shows partial volume averaging of the cartilage of patella and femur, not seen in the 3D DESS sequence **(2A)** due to isotropic imaging. Also note better evaluation of menisci and ligamentum mucosum on the FSPD sequence.

DESS sequence		SNR	CNR (synovial fluid SNR – cartilage SNR)
FA 25°	Cartilage	30.8	32.1
	Synovial fluid	62.9	
FA 45°	Cartilage	24.38	61.84
	Synovial fluid	86.22	
FA 60°	Cartilage	42.64	156.24
	Synovial fluid	198.88	
FA 90°	Cartilage	25.7	95.5
	Synovial fluid	121.22	



**3** Coronal MRI image of the wrist joint. **(3A)** 3D DESS (TR/TE 13.9/5.2 ms) FA 30° and **(3B)** 2D proton density with fat saturation (TR/TE 2500/46 ms). The arrow marks the triangular fibro-cartilage complex of the wrist joint.

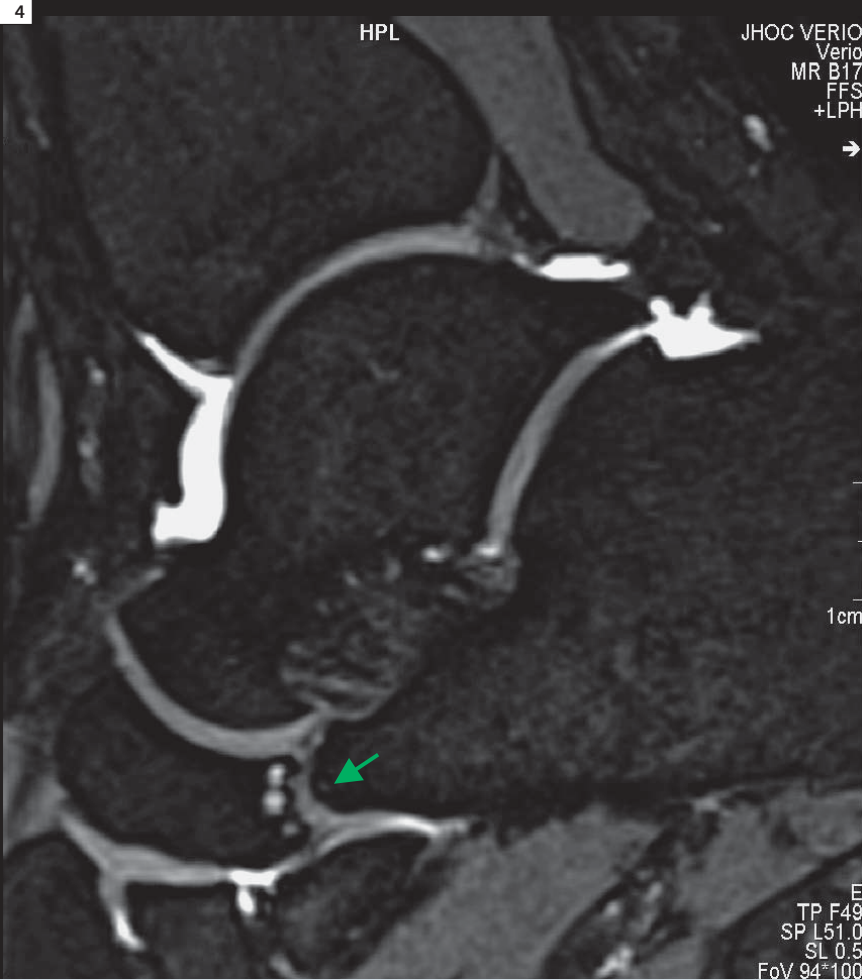
resolution in a relatively short imaging time [6]. In DESS, two or more gradient echoes are acquired. Each of these group of echoes are separated by a refocusing pulse and the combined data results in higher T2\* weighting, creating high signal in cartilage and synovial fluid [7].

The most important parameter which needs to be kept in mind while acquiring a DESS is the flip angle (FA). According to Hardy et al. [8], the appropriate flip angle for the 3D DESS sequence is 60 degrees. At this point, SNR and cartilage-synovial fluid CNR is highest. In figure 1, we show the knee joint at flip angles of 25, 45, 60 and 90 degrees with the table showing SNR and CNR at various angles. At FA >60°, cartilage-synovial fluid contrast decreased along a

curve obtained by the theoretical formula irrespective of TR [9].

Cartilage-synovial fluid contrast is comparable between water excited 3D DESS with a 60° FA and fat suppressed turbo spin echo proton density, which is commonly used for depicting cartilage. With both techniques, signal intensity of cartilage is intermediate and that of synovial fluid is high. Compared to 2D fat suppressed turbo spin echo proton density, slice thickness is typically thinner, suggesting the possibility that 3D DESS is capable of detecting smaller cartilage defects than the 2D technique. Lee et al. [10] have shown that fat suppressed 3D gradient echo sequences are better than 2D fat suppressed proton density sequences for differentiating grade 3 and grade 4 articular cartilage defects.

Water excited or fat suppressed 3D gradient echo imaging is recommended for measuring the exact cartilage thickness without partial volume artifacts, even though the CNR ratio between cartilage and bone marrow is relatively poor [11]. Chemical shift artifact can affect the cartilage-bone interface and fat suppression helps to reduce this. The disadvantages of 3D gradient echo imaging techniques are relatively long scan time, suboptimal contrast of other intra-articular and periarticular structures and metallic susceptibility artifacts. Fat suppressed turbo spin echo proton density is superior for other intra-articular and periarticular structures and is obtained in short imaging time, but it has the previously mentioned disadvantage of partial volume effects (Fig. 2).



**4** Sagittal 3D DESS image of the ankle joint showing the normal articular cartilage. Also note the fibrous calcaneonavicular coalition (arrow).

## Clinical implications

3D DESS allows quantitative assessment of cartilage thickness and volume with good accuracy and precision [12]. In comparison with other 3D GRE techniques tested in longitudinal knee osteoarthritis trial, DESS imaging exhibited similar sensitivity to changes in knee cartilage thickness over time [13]. It can be used in other joints such as ankle and wrist; however, there has been no comparative study between DESS and other 3D sequences in imaging of small joints (Figs. 3, 4).

## Summary

Cartilage imaging using the 3D DESS technique has many advantages including higher SNR, increased cartilage to fluid contrast and isotropic resolution, which helps to reduce partial volume effects.

### Contact

John A. Carrino, M.D., M.P.H.  
Associate Professor of Radiology and  
Orthopaedic Surgery  
The Russel H. Morgan Department  
of Radiology and Radiological Science  
Johns Hopkins University School of  
Medicine  
601 North Caroline St. / JHOC 5165  
Baltimore, MD  
USA  
carrino@jhmi.edu

## References

- Gold GE, Chen CA, Koo S, Hargreaves BA, Bangerter NK. Recent advances in MRI of articular cartilage. *AJR Am J Roentgenol* 2009 Sep;193(3):628-638.
- Kornaat PR, Reeder SB, Koo S, Brittain JH, Yu H, Andriacchi TP, et al. MR imaging of articular cartilage at 1.5T and 3.0T: comparison of SPGR and SSFP sequences. *Osteoarthritis Cartilage* 2005 Apr;13(4):338-344.
- Chavhan GB, Babyn PS, Jankharia BG, Cheng HM, Shroff MM. Steady-State MR Imaging Sequences: Physics, Classification, and Clinical Applications. *Radiographics* July-August 2008 July-August 2008;28(4):1147-1160.
- Gyngell ML. The application of steady-state free precession in rapid 2DFT NMR imaging: FAST and CE-FAST sequences. *Magn Reson Imaging* 1988 Jul-Aug;6(4):415-419.
- Bruder H, Fischer H, Graumann R, Deimling M. A new steady-state imaging sequence for simultaneous acquisition of two MR images with clearly different contrasts. *Magn Reson Med* 1988 May;7(1):35-42.
- Welsch GH, Scheffler K, Mamisch TC, Hughes T, Millington S, Deimling M, et al. Rapid estimation of cartilage T2 based on double echo at steady state (DESS) with 3 Tesla. *Magn Reson Med* 2009 Aug;62(2):544-549.
- Crema MD, Roemer FW, Marra MD, Burstein D, Gold GE, Eckstein F, et al. Articular Cartilage in the Knee: Current MR Imaging Techniques and Applications in Clinical Practice and Research. *Radiographics* January-February 2011 January-February 2011;31(1):37-61.
- Hardy PA, Recht MP, Piraino D, Thomasson D. Optimization of a dual echo in the steady state (DESS) free-precession sequence for imaging cartilage. *J Magn Reson Imaging* 1996 Mar-Apr;6(2):329-335.
- Moriya S, Miki Y, Yokobayashi T, Ishikawa M. Three-dimensional double-echo steady-state (3D-DESS) magnetic resonance imaging of the knee: contrast optimization by adjusting flip angle. *Acta Radiol* 2009 Jun;50(5):507-511.
- Lee SY, Jee WH, Kim SK, Koh IJ, Kim JM. Differentiation between grade 3 and grade 4 articular cartilage defects of the knee: fat-suppressed proton density-weighted versus fat-suppressed three-dimensional gradient-echo MRI. *Acta Radiol* 2010 May;51(4):455-461.
- Gold GE, McCauley TR, Gray ML, Disler DG. Special Focus Session. *Radiographics* 2003 September 01;23(5):1227-1242.
- Eckstein F, Hudelmaier M, Wirth W, Kiefer B, Jackson R, Yu J, et al. Double echo steady state magnetic resonance imaging of knee articular cartilage at 3 Tesla: a pilot study for the Osteoarthritis Initiative. *Ann Rheum Dis* 2006 Apr;65(4):433-441.
- Wirth W, Nevitt M, Hellio Le Graverand MP, Benichou O, Dreher D, Davies RY, et al. Sensitivity to change of cartilage morphometry using coronal FLASH, sagittal DESS, and coronal MPR DESS protocols--comparative data from the Osteoarthritis Initiative (OAI). *Osteoarthritis Cartilage* 2010 Apr;18(4): 547-554.